

THE PRESENCE OF ELECTROCARDIOGRAPHIC CHANGES IN
NICOTINIC ACID DEFICIENCY AND THEIR ELIMINATION
BY NICOTINIC ACID

M. RACHMILEWITZ, M.D., AND K. BRAUN, M.D.

JERUSALEM

THE only vitamin deficiency so far known to be associated with cardiovascular disturbances is that of vitamin B₁, e.g., beriberi heart disease, which is manifested by cardiac enlargement and heart failure. Cardiac insufficiency caused by vitamin B₁ deficiency may occur also in alcoholic addicts, together with other manifestations of avitaminosis B₁ (Weiss and Wilkins¹). In such cases, vitamin B₁ administration promptly results in clearing up the cardiac failure and in a decrease in the size of the heart.

Cardiovascular symptoms have also been observed in another type of B avitaminosis, namely, pellagra, particularly in the acute form. The symptoms consist mainly of dyspnea on exertion and palpitation. Cardiac enlargement and failure are not, however, mentioned as a special feature of pellagra. Electrocardiographic studies in pellagra have disclosed abnormalities in a large percentage of cases, consisting mainly in alteration of the S-T segment and inversion of the T wave (Feil²). Since, in deficiency diseases in man, several factors of the vitamin B complex may be lacking simultaneously, and since vitamin B₁ deficiency is known to be associated with changes in the electrocardiogram, the electrocardiographic changes found in pellagra were attributed to B₁ deficiency. Mainzer and Krause³ found a high incidence of abnormal electrocardiograms in pellagrins in Egypt, but believed that these changes were not characteristic of pellagra, and that their occurrence was not sufficient to conclude that they are caused by deficiency of nicotinic acid. As there was a parallelism between the course of the disease and the electrocardiographic changes, which disappeared rapidly in one case after nicotinic acid therapy, they assumed that a causal relationship may exist between these changes and the pellagra.

In this paper we report the effect of nicotinic acid on the electrocardiograms in two cases of nicotinic acid deficiency. Both patients presented the typical picture of pellagra, including pellagra dermatitis, and responded to treatment. A year later in one case, and six months later in the other case, all of the visceral manifestations of pellagra reappeared, but pellagra dermatitis was absent. In both cases there were marked abnormalities in the electrocardiograms, and in both instances

Medical Department "B," Rothschild-Hadassah-University Hospital, Jerusalem.
Received for publication March 11, 1943.

a series of experiments was carried out to ascertain whether or not the nicotinic acid had a specific effect on the electrocardiographic changes.

REPORT OF CASES

CASE 1.—A 30-year-old woman who had been suffering from repeated attacks of diarrhea for many months was admitted in a state of severe deficiency. She had stomatitis, glossitis, severe diarrhea, marked anemia, and mental disturbances. There was marked edema of the lower extremities, as well as neuritic manifestations. The patient complained of palpitation and precordial pain. The heart was normal in size, and there were no signs of cardiac insufficiency. The heart sounds were feeble, the pulse rate accelerated, and the blood pressure, 110/80.

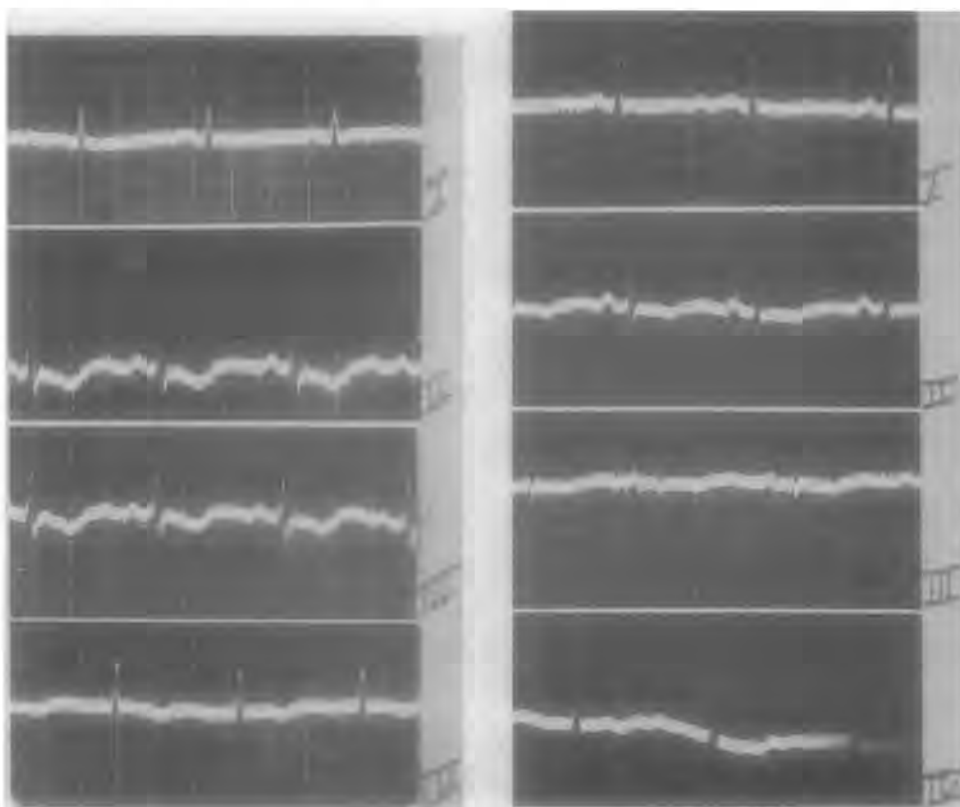


Fig. 1A.

Fig. 1B.

Fig. 1A.—Electrocardiogram taken before treatment. Flat T_1 and inverted T wave in Leads II, III, and IV.

Fig. 1B.—After six days of treatment with nicotinic acid. T wave in Leads II, III, and IV slightly inverted.

The first electrocardiogram (Fig. 1A) showed marked changes, namely, a flat T_1 and an inverted T_2 , T_3 , and T_4 . The patient was given an ordinary diet, plus 500 mg. of nicotinic acid daily by mouth. Her mental symptoms, stomatitis, and glossitis responded promptly; also, the diarrhea diminished in severity. An electrocardiogram taken six days after

the beginning of treatment (Fig. 1B) showed marked improvement. The T waves were now only slightly depressed in Leads II and III, and not inverted as before. Nicotinic acid was now discontinued, and, during the following five days, only vitamin B₁ was given (40 mg. daily, intravenously). This change in treatment was followed by an increase in diuresis and subsidence of the edema, but the mental and gastrointestinal disturbances became worse. Another electrocardiogram (Fig. 1C) disclosed that the abnormalities which were present on admission

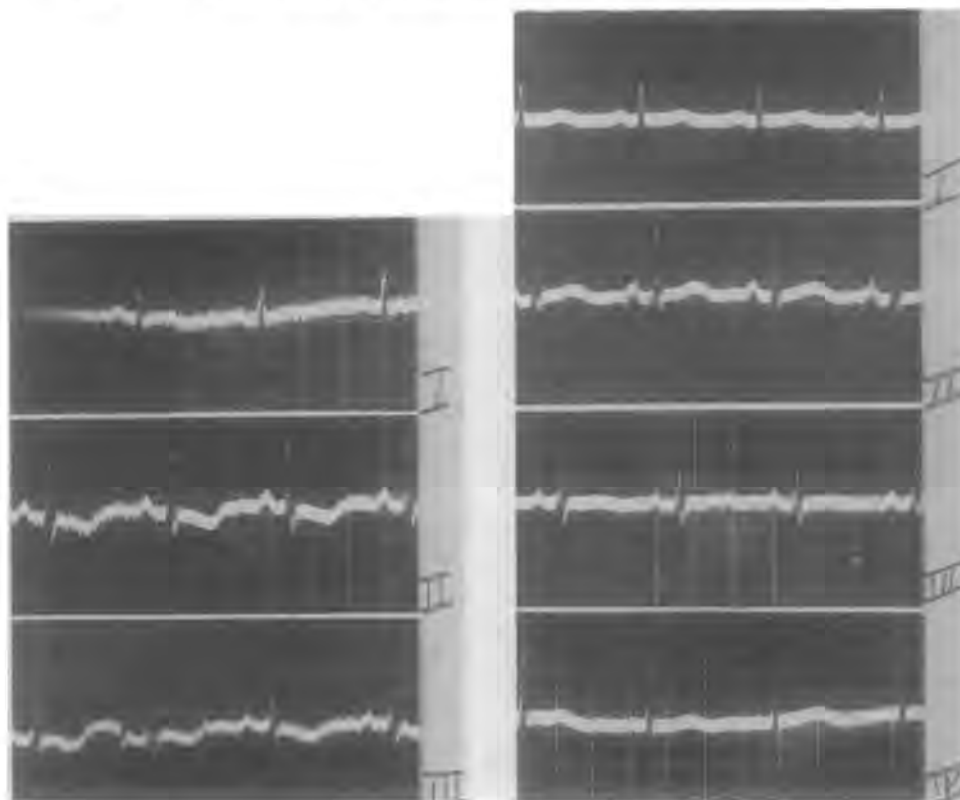


Fig. 1C.

Fig. 1D.

Fig. 1C.—Nicotinic acid discontinued. Only B₁, 40 mg. daily, given. Electrocardiographic changes similar to Fig. 1A.

Fig. 1D.—After fourteen days of renewed nicotinic acid administration, practically normal electrocardiogram.

had reappeared. Nicotinic acid was again given, with the result that, a fortnight later, a practically normal tracing was obtained. The T waves became positive in Leads I, II, and IV, and isoelectric in Lead III (Fig. 1D). Intercurrent infections repeatedly exacerbated the deficiency state, in spite of continuous nicotinic acid administration. These exacerbations and the improvement which followed them were reflected in the subsequent electrocardiograms.

CASE 2.—The patient was a 50-year-old man who was suffering from intestinal amebiasis. The first attack occurred in the summer of 1941. After three months of continuous diarrhea, the patient developed the

typical signs of pellagra; the latter responded promptly to nicotinic acid. In February, 1942, he again had an attack of diarrhea, which, after one month, produced a severe deficiency state. The patient was readmitted to the hospital March 26. This time all the visceral manifestations of nicotinic acid deficiency were present, particularly gastrointestinal and mental disturbances, but no cutaneous lesions were present. The patient was emaciated and dehydrated. The pulse was slow and feeble, the heart sounds dull. The heart was normal in size, both on clinical and fluoroscopic examination. The blood pressure was 85/80. There were no signs

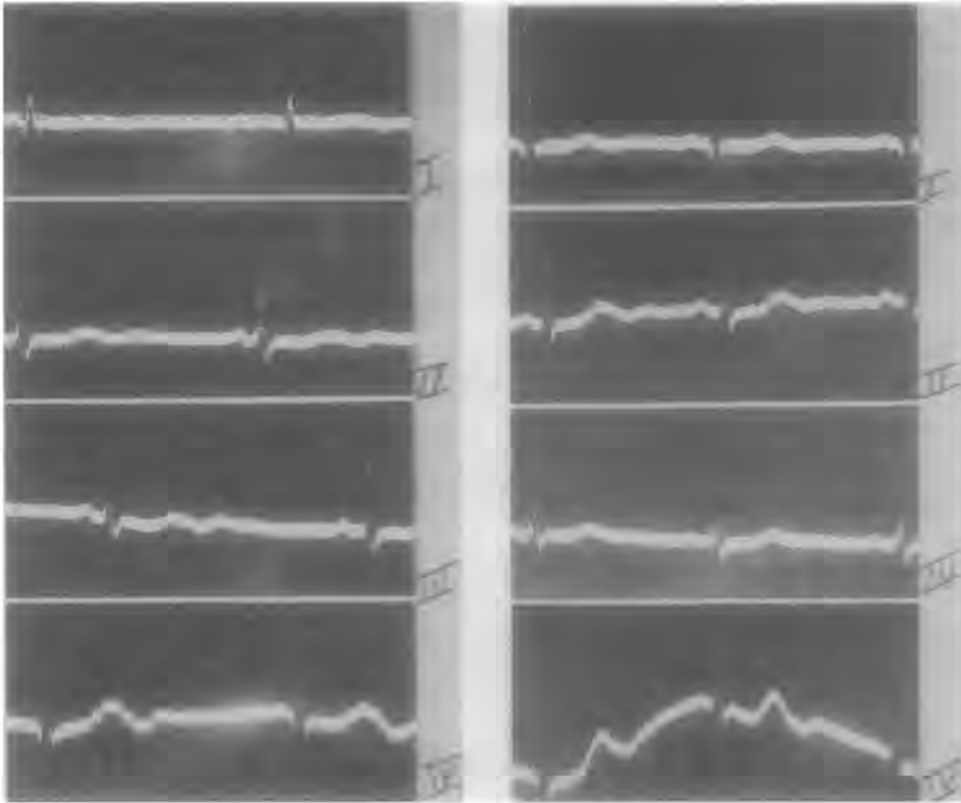


Fig. 2A.

Fig. 2B.

Fig. 2A.—Marked changes in the T wave in all leads.

Fig. 2B.—After six days of treatment with nicotinic acid, electrocardiogram normal.

of heart failure and no edema was present. The electrocardiogram, however, disclosed pronounced changes in the T waves in all leads (Fig. 2A). The patient was first given a continuous intravenous infusion of saline (4 liters in three days). His condition improved noticeably, although the diarrhea continued and the condition of the tongue and mouth did not change. The second electrocardiogram, made March 31, showed the same changes as before. Nicotinic acid treatment was now begun. The patient was given 500 mg. of nicotinic acid by mouth and 100 mg. intravenously for six days, together with an ordinary mixed diet. At the end of this period the diarrhea stopped completely and the

appearance of the mucous membrane of the tongue and the buccal parts of the lips improved considerably, although he still complained of soreness and a burning sensation. The electrocardiogram made on April 7 (Fig. 2*B*) was perfectly normal. The T waves had become upright in all leads. The patient remained in good condition in spite of discontinued medication, and his electrocardiograms also remained normal. Thus, in this case as in the preceding one, the administration of nicotinic acid had a prompt and definite effect on the heart, as evidenced by the electrocardiograms.

COMMENT

Therapeutic tests in our cases justify the conclusion that the electrocardiographic changes which occur in pellagra are due specifically to nicotinic acid deficiency. In both cases the changes in the electrocardiogram were shown to be reversible.

What explanation can be offered for the direct effect of nicotinic acid on the heart?

Nicotinic acid is known to produce vasodilatation of the skin, as indicated by flushing in various parts of the body after administration of this drug. It is conceivable that nicotinic acid has the same effect on the coronary vessels, thus increasing the blood supply of the heart. But it is doubtful whether blood vessels of visceral organs are at all affected by nicotinic acid. Investigations have shown that the blood flow through the brain is hardly increased by this substance,⁴ although the pial vessels were found to be dilated.⁵ Furthermore, the vasodilator action of nicotinic acid is, in general, transient in character; flushing of the skin usually disappears within half an hour.⁶ It seems likely, therefore, that the influence of nicotinic acid on the electrocardiographic changes is due to some more fundamental action.

The most conspicuous changes produced in the electrocardiogram by nicotinic acid were observed in the T wave. Inasmuch as metabolic changes in the heart muscle are reflected in the T wave (anoxemia, thyroid deficiency, and avitaminosis B₁), any factor affecting the metabolism of the heart muscle may affect also the character of the T wave.

Nicotinic acid is the chemically active fraction of the coenzymes which are essential for the intermediate metabolism of carbohydrates. A marked diminution of coenzyme I in the striated muscle of human subjects, produced by deficiency of nicotinic acid, was recently reported by Axelrod, Spies, and Elvehjem,⁷ who assume that the decrease in the coenzyme content may affect the ability of the human muscle to carry out its oxidative function. The symptoms and signs of avitaminosis are regarded as the results of chemical disturbances of cellular function due to failure of coenzyme (Sydenstricker⁸). It seems logical, therefore, to assume that an altered metabolic state of the heart is due to coenzyme deficiency; the resulting changes are reversible, i.e., they disappear promptly after the administration of nicotinic acid.

SUMMARY

Two cases of nicotinic acid deficiency are reported; in both there were marked changes in the electrocardiograms, particularly in the T waves. Nicotinic acid administration resulted in prompt improvement in the nature of the electrocardiographic pattern, thus suggesting a specific effect of nicotinic acid on the heart, most probably the heart muscle.

REFERENCES

1. Weiss, Soma, and Wilkins, Robert W.: The Nature of the Cardiovascular Disturbances in Nutritional Deficiency States (Beriberi), *Ann. Int. Med.* **11**: 104, 1937.
2. Feil, Harold: A Clinical Study of the Electrocardiogram and of the Phases of Cardiac Systole in Pellagra, *AM. HEART J.* **11**: 173, 1936.
3. Mainzer, F., and Krause, M.: The Electrocardiogram in Pellagra, *Brit. Heart J.* **2**: 85, 1940.
4. Lomann, J., Rinkel, M., and Myerson, A.: Intracranial and Peripheral Vascular Effects of Nicotinic Acid, *Am. J. M. Sc.* **202**: 211, 1941.
5. Moore, M. T.: Treatment of Multiple Sclerosis With Nicotinic Acid and Vitamin B₁, Preliminary Report, *Arch. Int. Med.* **65**: 1, 1940.
6. Rachmilewitz, M., and Gluck, H. J.: Treatment of Pellagra With Nicotinic Acid, *Brit. Med. J.* **2**: 346, 1938.
7. Axelrod, A. E., Spies, Tom D., and Elvehjem, C. A.: The Effect of Nicotinic Acid Deficiency Upon the Coenzyme I Content of the Human Erythrocytes and Muscle, *J. Biol. Chem.* **138**: 667, 676, 1941.
8. Sydenstricker, V. P.: Present Status of Nicotinic Acid, *Arch. Int. Med.* **67**: 746, 1941.