

## THE FETAL BOVINE THYROID: MORPHOGENESIS AS RELATED TO IODINE ACCUMULATION<sup>1</sup>

ALEXEI A. KONEFF, C. W. NICHOLS, JR., J. WOLFF,<sup>2</sup>  
AND I. L. CHAIKOFF

*From the Divisions of Anatomy and Physiology of the University  
of California Medical School*

BERKELEY, CALIFORNIA

IN THE fetal calf, which has a gestation period of approximately 285 days, thyroxine-like iodine can be detected in the thyroid gland on the sixtieth day of intrauterine life. Thereafter, the amounts of thyroxine-like and total iodine in the gland increase steadily, and the rates of increase of these two iodine fractions have been shown to be related exponentially to fetal body weight, length, and age (Wolff *et al.*, 1949). Since, in addition, the *concentration* of iodine in the developing gland (i.e., mg. of iodine per 100 gm. fresh tissue) appeared to increase progressively, it was postulated that with increasing age, the fetal thyroid acquired an increased capacity for iodine storage.

In the present investigation, we have attempted to correlate the morphogenesis of the gland with its iodine content. Since the follicle might be regarded as the structural and functional unit of the gland, we sought to determine the relation of its development to the capacity of the gland to store iodine.

### EXPERIMENTAL

Fifty-nine thyroid glands were collected from fetal calves ranging in age from 53 to 265 days in intrauterine life (gestation 278–285 days). The age of each fetus was determined as described in an earlier report (Nichols *et al.*, 1949). The methods employed for iodine determinations have also been described (Wolff *et al.*, 1949). The glands were fixed in Bouin's fluid, embedded in nitrocellulose, and sectioned at six micra. The sections were stained with hematoxylin and eosin and also by the Malloray-Azan method.

### RESULTS

The thyroid glands have been grouped according to stages of histogenesis as shown in Table 1. At the earliest stage (53 to 70 days), the glands consisted of proliferating masses of branching epithelial

---

Received for publication June 8, 1949.

<sup>1</sup> Aided by grants from the U. S. Public Health Service and the Committee on Endocrinology of the National Research Council.

<sup>2</sup> U. S. Public Health Fellow.

plates or cords, one to three cells wide, surrounded by well developed blood and lymphatic capillaries (Plate I, fig. 1). The interstitial mesenchymal connective tissue was not abundant at that time, except in the center of the lateral lobes or in the isthmus. Many nuclei were undergoing mitosis, indicating rapid growth of the epithelial cords. The individual cells adhered to one another, but were sharply outlined. The abundant, lightly staining cytoplasm of these cells contained no visible colloid droplets.

Colloid droplets (staining with either aniline blue or with orange G) first made their appearance in the cell cytoplasm of thyroid glands in 75- to 88-day-old fetuses. These droplets moved toward the cell

TABLE 1. IODINE CONTENTS OF FETAL THYROIDS

Estimated age range of group	Number of glands examined		Average iodine values mg. per cent			Reference to figures (Plates I-III)
	Histologically	Chemically	Thyroxine	Non-thyroxine	Total*	
days						
53-70	7	4	3.0	14.1	17.1 ± 5.5	1
75-88	6	12	4.0	7.3	11.3 ± 1.5	2-6 and 9
90-105	14	14	2.9	9.6	12.7 ± 2.0	10
106-118	6	9	6.3	11.6	17.9 ± 3.1	11
120-133	4	6	5.5	14.5	20.0 ± 4.5	12
135-152	7	11	8.5	24.0	32.6 ± 2.9	13
153-172	5	13	10.8	23.3	34.1 ± 4.8	14
175-205	3	4	19.1	48.0	67.0 ± 7.1	15
218-265	5	8	35.1	82.4	118.0 ± 15.0	16

$$* \text{ Standard error of mean } = \sigma_{\bar{x}} = \sqrt{\frac{\sum_i^n (x_i - \bar{x})^2}{n(n-1)}} .$$

border and eventually passed into intercellular spaces marking the center of the future follicle (figs. 3 and 4).

Steps in the development of true follicles are clearly shown in figs. 4, 5, and 6. During the follicle formation, the regularity of cord arrangement became less distinct (fig. 2).

Photomicrographs 9 to 16 (all of the same magnification) show the gradual development of the thyroid parenchyma. In the process of reconstruction into follicles, the mass of epithelial cords (now constituting interfollicular tissue) gradually diminishes and, in the later stages of thyroid development, this interfollicular tissue is represented by rather small islets of cells. At the periphery of the gland, or, in later stages, at the periphery of the lobules, the cord arrangement remains as an uninterrupted rim up to 150th day of intrauterine life. This tissue apparently serves as a reserve material for the growing thyroid since numerous mitoses and very young follicles are present.

Intracellular colloid formation and growth of the follicles were not appreciable for a period of approximately 60 days after their first appearance. There also was no major increase in total iodine content in the glands at that time. As gestation progressed, however, the rate of follicular development clearly increased, as did the amounts of colloidal material in the lumina of the follicles, and the intracellular colloid droplets in the follicular epithelium. This intracellular activity accelerated notably during the last 2-2½ months of pregnancy. At that time, fetal thyroids reached almost complete development and a distinct increase in total iodine content was recorded. The epithelial cells which now had attained their maximum size were mostly columnar. Nuclei were round or oval in shape and vesicular in character. The apical portion of the cytoplasm of the follicular cells of many follicles was filled with numerous discrete colloid droplets (figs. 7 and 8). These figures also show the manner in which colloid droplets pass into the follicular cavity. This picture of secretory activity was not unlike that described by De Robertis in his studies on colloid secretion by the follicular epithelium (1941, 1942, and 1949).

#### DISCUSSION

In fetuses ranging from 53 to 70 days in age, the thyroid contained about three mg. per cent thyroxine and about 17 mg. per cent total iodine. In contrast, the concentrations of these two iodine fractions in the livers of three fetuses aged 62, 68, and 70 days—though too low to permit an accurate quantitative measure—were less than one-tenth those of their respective thyroid glands (Wolff and Nichols, 1949).

#### EXPLANATION OF PLATES

Photomicrographs were taken with 4 mm. objective (figs. 1 and 2), with oil immersion objective (figs. 3 to 8), and with 16 mm. objectives (figs. 9 to 16). Magnification  $\times 400$ ,  $\times 750$ , and  $\times 150$  respectively.

FIG. 1. An area from the central region of the thyroid gland of 63-day-old calf fetus. Note the arrangement of cells into quite regular cords. No intracellular colloid or follicles are present.

FIG. 2. An area from the thyroid gland of 78-day-old calf fetus. Note a few very young follicles. Also note that the cord arrangement became less regular.

The following figures (3 to 6) show initial stages of development of the follicles.

FIG. 3. Individual colloid droplets stainable with aniline blue or orange G can be seen in the cytoplasm (arrow).

FIG. 4. First drop of colloid located between two oblong, neighboring cells of the cord (arrow).

FIG. 5. Young follicle showing individual colloid drops not yet coalesced. Also note that one droplet of colloid is passing from the apical region of the cell into the lumen; note indented nucleus.

FIG. 6. Young follicle having many characteristics shown in fig. 5 but containing faintly vacuolated, irregular mass of fusing colloid droplets.

FIG. 7. Follicular epithelium from near-term gland showing two cells apical portions of which are ready to be cast off into the lumen.

FIG. 8. High columnar epithelium from the thyroid of fetus near-term showing massive accumulation of stainable colloid droplets in the apical zone of the cytoplasm and their passage into the lumen.

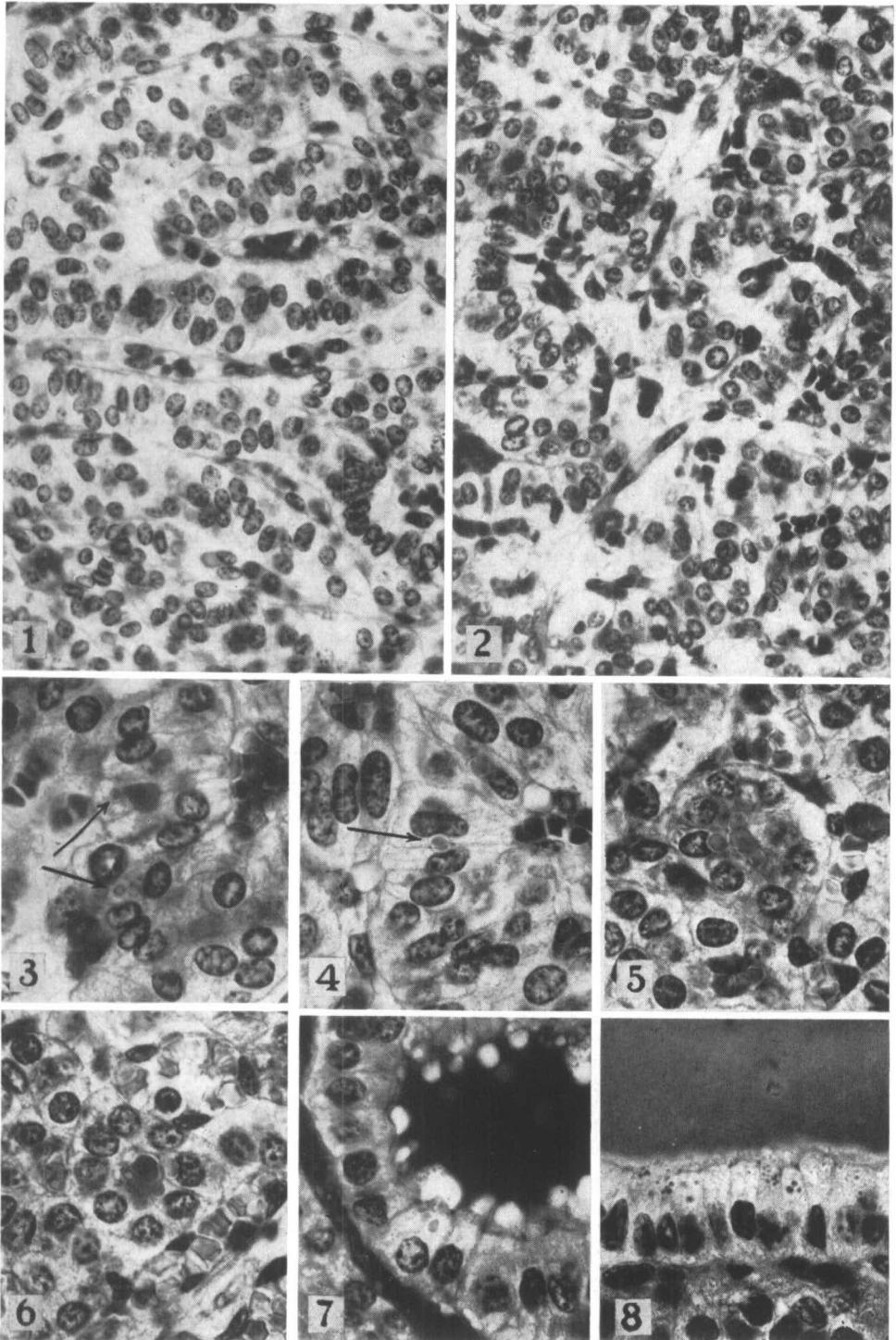


PLATE I

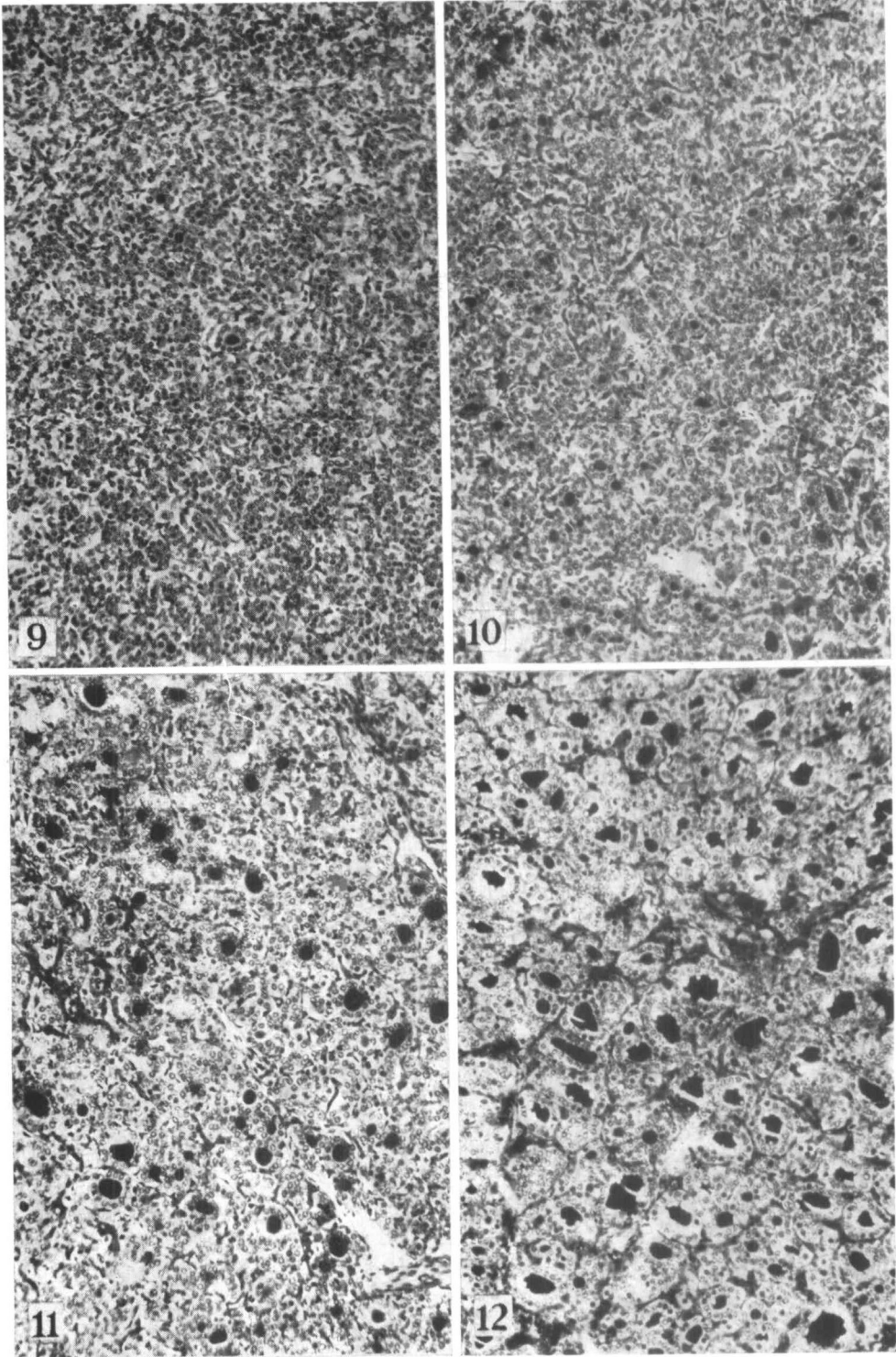


PLATE II

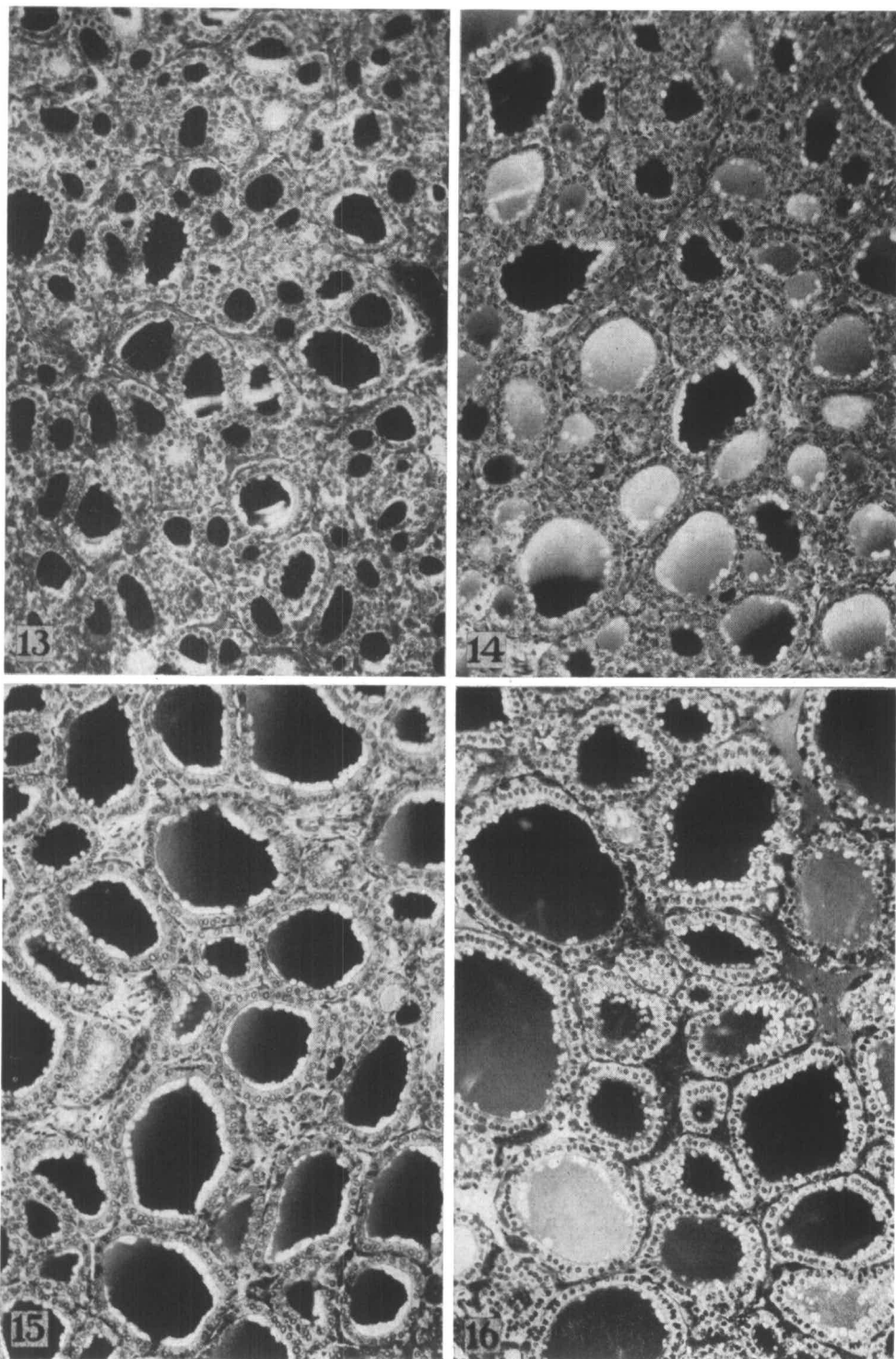


PLATE III

FIGS. 9 TO 12 ON PLATE II AND FIGS. 13 TO 16 ON PLATE III ARE PHOTOMICROGRAPHS REPRESENTING THYROIDS OF CALVES, 88, 90, 108, 125, 135, 155, 175, AND 254 DAYS OF INTRA-UTERINE LIFE RESPECTIVELY. NOTE PROGRESSIVE NUMERICAL INCREASE OF TYPICAL THYROID FOLLICLES AND THEIR DEVELOPMENT ACCOMPANIED BY GROWTH AND DEVELOPMENT OF FOLLICULAR EPITHELIUM. ALSO NOTE GRADUAL DIMINUTION OF INTERFOLLICULAR NESTS OF CELLS.

Thus concentration and storage of organic iodine in the fetal thyroid tissue takes place not only while the gland is still devoid of its characteristic architecture, but even prior to any histological manifestation of this specific function (intracellular colloid droplets). Follicular arrangement of thyroid epithelium is, therefore, not a prerequisite to iodine storage by this tissue.

Similar findings have been reported for the fetal pig by Rankin (1941) who detected thyroxine and diiodotyrosine in the thyroids of 52-day-old fetuses (gestation period 114 days) at a time when their thyroids contained neither follicles nor colloid.

Hogben and Crew (1923) reported follicle differentiation and minute colloid masses at three months in bovine fetal glands. In the same species, Aron (1931) found small amounts of stainable colloid at 15–18 cm. stage (corresponding to about 90 days of pregnancy as calculated here), whereas Abbott and Prendergast (1937) described colloid and follicle formation during the second month of life. In our series of calf thyroids, colloid was first detected *within the cytoplasm* of individual cells and *in the lumen* of very young follicles on the 75th day of intrauterine life.

The following may be considered as the first stages of the histological manifestation of secretory activity in early fetal thyroids: a) the appearance of intracellular colloid droplets and beginning of follicle formation in the glands of about 75- to 88-day-old fetuses; b) the presence of completely formed, although very small, follicles at approximately 90 days. In spite of this definite advance in their histological development, the fetal thyroids showed no major changes in the amounts of iodine stored, either during this period or in the following few weeks.

In the following months (from 120 to 205 days), the increase in the concentration of organic iodine was accompanied by the gradual histological development shown in figs. 12 to 15. Histological manifestations of activity, as judged by production and storage of colloid, in glands of these age groups differed only in degree and not in general character. The average values for total iodine were 20.0, 32.6, 34.1, and 67.0 mg. per cent for the groups represented by photographs 12 to 15, respectively. In the final months of gestation, total organic iodine content reached its maximum, averaging now 118 mg. per cent. This increase in storage capacity of the thyroid gland was accompanied by a very marked rise of functional activity of the follicular cells.

#### SUMMARY

Thyroxine-like and other organically bound iodine compounds appear in the fetal calf thyroid between the 53d and 70th days, a time prior to the appearance of histologically detectable intracellular colloid or follicle formation, which takes place at 75–88 days. Since the livers of fetuses aged 62–70 days contain practically no iodine,

the presence of these organic iodine compounds was considered a manifestation of iodine storage by the gland.

From the 75th to 118th day, the predominating features of the developing thyroid were the appearance of colloid and differentiation of the parenchyma without a pronounced increase in the iodine content of the gland.

Between the fourth and seventh month, gradual development of the fetal thyroid gland was accompanied by a steady increase in its organic iodine content.

An appreciable increase in organic iodine content occurred near term, and was accompanied by definite histological manifestations of increased functional activity of the follicular epithelium.

#### REFERENCES

- ABBOTT, A. C., AND J. PRENDERGAST: *Canad. M. A. J.* 36: 228. 1937.  
ARON, M.: *Bull. Biol. France* 65: 438. 1931.  
DE ROBERTIS, E.: *Am. J. Anat.* 68: 377. 1941.  
DE ROBERTIS, E.: *Anat. Rec.* 84: 125. 1942.  
DE ROBERTIS, E.: *Ann. N. Y. Acad. Sci.* 50: 317. 1949.  
HOGBEN, L. T., AND F. A. E. CREW: *Brit. J. Exp. Biol.* 1: 1. 1923.  
NICHOLS, C. W., JR., I. L. CHAIKOFF AND J. WOLFF: *Endocrinology*, 44: 502. 1949.  
RANKIN, R. M.: *Anat. Rec.* 80: 123. 1941.  
WOLFF, J., I. L. CHAIKOFF AND C. W. NICHOLS, JR.: *Endocrinology*, 44: 510. 1949.  
WOLFF, J., AND C. W. NICHOLS, JR.: Unpublished observations. 1949.