

Iodide Mumps

Acute Sialadenitis After Contrast Administration for Angioplasty

Vijay G. Kalaria, MD; Renata Porsche, RN, MS; Ling S. Ong, MD

A 63-year-old black woman with hypertension, diabetes mellitus, and end-stage renal disease who was on dialysis underwent percutaneous intervention of a right coronary artery. A total of 100 cc of Optiray (74% Ioversol, a nonionic low-osmolar contrast agent with 350 mg/mL of organically bound iodine) was used during the procedure. A few hours after the procedure, the patient noticed swelling and pain in the upper neck region. She recalled a history of mumps in childhood and was on aspirin, ticlopidine, losartan, and thyroxin.

Physical examination revealed an afebrile patient with a regular heart rate of 75 bpm and a blood pressure of 109/50 mm Hg. Bilateral, diffuse submandibular gland enlargement and mild parotid gland enlargement were noted (Figure 1). Oral mucosa was dry without erythema, abscess, or ulcers. Contrast-induced acute sialadenitis (iodide mumps) was suspected on the basis of clinical presentation. Treatment with analgesics and dialysis led to complete resolution of submandibular gland swelling (Figure 2). She has had no recurrence of sialadenitis and has remained asymptomatic since discharge.

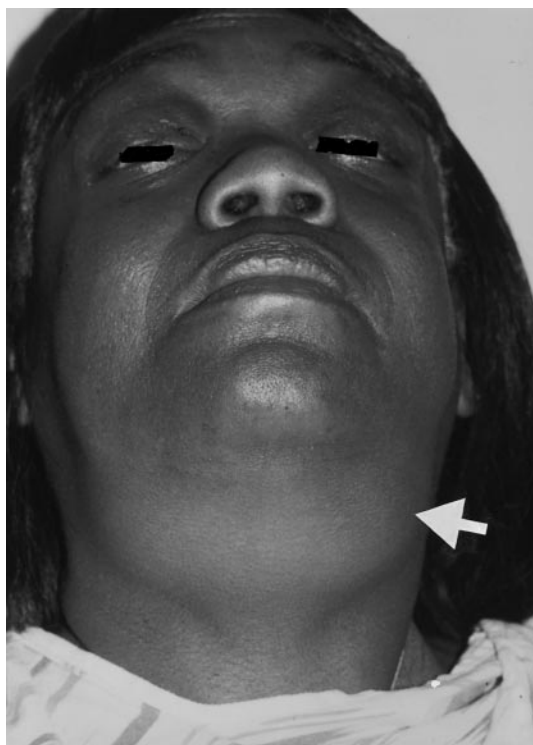


Figure 1. Diffuse, bilateral, symmetrical submandibular gland enlargement 1 day after angioplasty.

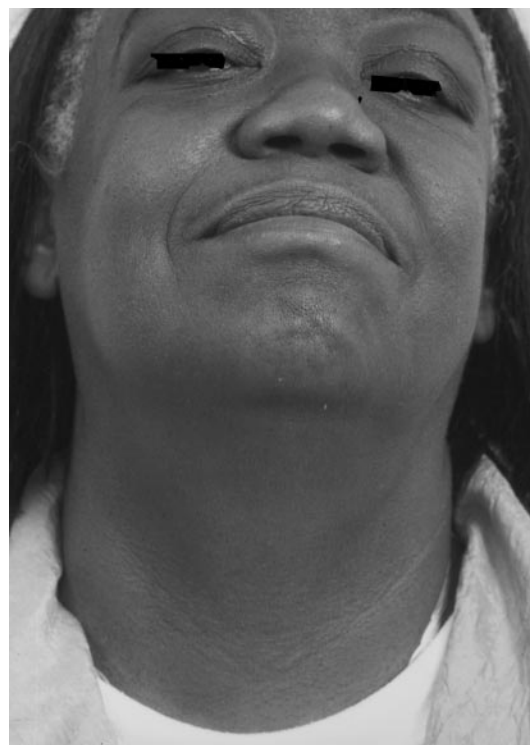


Figure 2. Resolution of submandibular gland enlargement after dialysis treatment 2 days after angioplasty.

From the Krannert Institute of Cardiology, Department of Medicine, Indiana University, Indianapolis, Ind (V.G.K.), and Rochester General Hospital, Cardiology Unit, Department of Medicine, University of Rochester, Rochester, NY (R.P., L.S.O.).

Correspondence to Vijay G. Kalaria, MD, Clinical Assistant Professor of Medicine, Associate Director, Cardiac Catheterization Laboratories and Interventional Cardiology, Krannert Institute of Cardiology, Indiana University, University Hospital, UH-5510R, 550 North University Blvd, Indianapolis, IN 46202-5250. E-mail vkalaria@iupui.edu

The editor of Images in Cardiovascular Medicine is Hugh A. McAllister, Jr, MD, Chief, Department of Pathology, St Luke's Episcopal Hospital and Texas Heart Institute, and Clinical Professor of Pathology, University of Texas Medical School and Baylor College of Medicine.

Circulation encourages readers to submit cardiovascular images to the *Circulation* Editorial Office, St Luke's Episcopal Hospital/Texas Heart Institute, 6720 Bertner Ave, MC1-267, Houston, TX 77030.

(*Circulation*. 2001;104:2384.)

© 2001 American Heart Association, Inc.

Circulation is available at <http://www.circulationaha.org>