

Mammary Gland Dysplasia in Iodine Deficiency

Studies in Rats

Bernard A. Eskin, MD, Doris G. Bartuska, MD,

Marvin R. Dunn, MD, Ginette Jacob, MD, and Mary B. Dratman, MD

Epidemiological studies suggest that persons living in areas of normal iodine availability show less breast cancer than those living in iodine-deficient areas.^{1,2} World Health Organization investigations, recently published,³ have revealed that a large segment of the population in the United States and other parts of the world lives in areas of limited iodine availability. In addition, there appears to be statistical evidence of an increased incidence of

From the departments of obstetrics and gynecology, medicine, and pathology, Woman's Medical College of Pennsylvania, Philadelphia.

Read in part before the session on hematology, immunology and tumor of the Sixth Multidiscipline Research Forum during the 115th annual convention of the American Medical Association, Chicago, June 28, 1966.

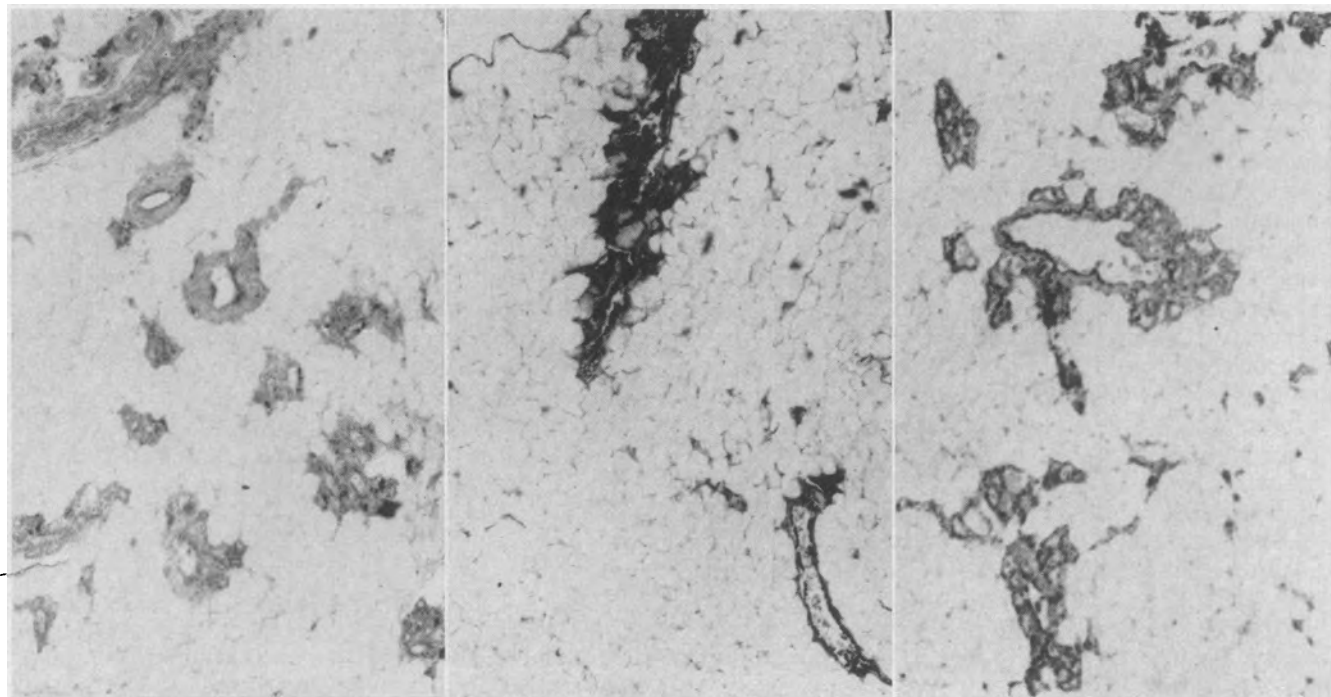
Reprint requests to 3300 Henry Ave, Philadelphia 19129 (Dr. Eskin).

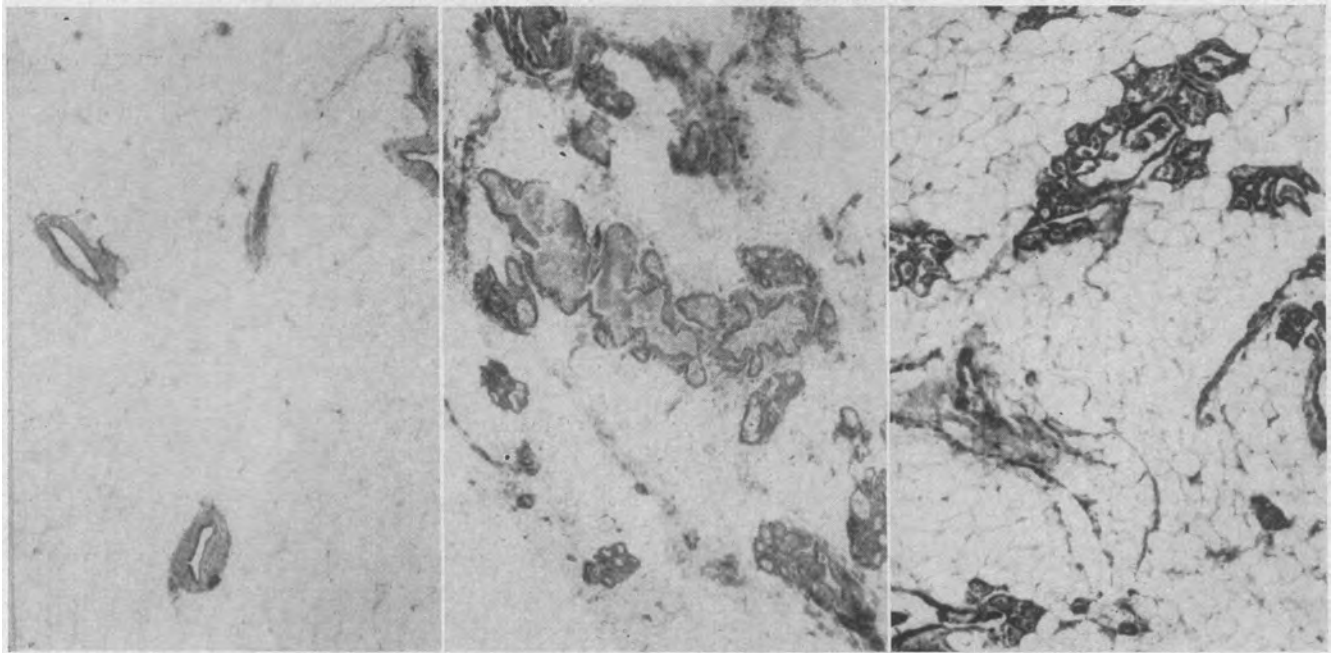
breast malignancy in hypothyroidism.⁴⁻⁶ Our results imply that iodine deficiency may be involved in these thyroid-breast relationships.

The breasts of chronically iodine-deficient female rats treated with testosterone were observed to be considerably larger than their normally fed, testosterone-injected litter-mate controls. No reports directly pertaining to this observation were found in the literature. Therefore, we decided to carry out a systematic investigation of the influence of iodine deficiency on the resting and sex-hormone-treated breasts of female rats. The changes seen were compared with the breast tissue responses found in normally fed euthyroid and normally fed hypothyroid (propylthiouracil-treated) rats.

Iodine deficiency was found to enhance the re-

1. Effect of hormones on breast of normally fed rat: Left, No hormones. Center, Estrogen. Right, Testosterone (hematoxylin and eosin, $\times 24$).





2. Effect of hormones on breast of chronically iodine-deficient rat: Left, No hormones. Center, Estrogen. Right, Testosterone (hematoxylin and eosin, $\times 24$).

sponse of rat breast tissues to sex-hormone injections; the breast changes seen in the iodine-deficient rat were clearly distinguishable from those induced by sex hormones in the hypothyroid and in the euthyroid rat. Estrogen and testosterone administration to iodine-deficient hypothyroid rats resulted in lesions which mimic human cystic disease of the breast. Thus the present study suggests another physiologic factor which may act to modify breast-sex steroid interactions.

Materials and Methods

One hundred and fifty-six female CFN strain (Carworth Farms) albino virgin rats initially weighing 180 to 228 gm were divided into four major categories: iodine-deficient, normally fed propylthiouracil-treated, propylthiouracil-treated iodine-deficient, and age-paired normally fed controls. Rats were made chronically iodine deficient by the Remington diet and deionized drinking water given to them ad libitum for 12 weeks before the study was begun. On this regimen, rats grew and gained weight at the same rate as did their normally fed controls. Hypothyroidism was produced by the daily subcutaneous injection of 2 mg propylthiouracil suspended in 0.5 cc deionized water, with an equal quantity of gum acacia added as a dispersing agent, for ten days prior to and throughout the period of treatment with sex steroids. Each of these major groups of rats was further separated into groups receiving (1) sesame oil, (2) estradiol benzoate, or (3) testosterone. Estradiol benzoate (50 μ g) and testosterone (2.5 mg) were injected subcutaneously daily in 0.1 cc sesame oil for a 20-day period. All animals received the same injection volume of water and sesame oil throughout.

At the end of the 20-day period, the rats were injected with 5 μ c of carrier-free sodium iodide I 131 intraperitoneally one hour before being killed. The animals were then killed with ether, and the two inguinal and two inferior abdominal mammary glands of each rat were dissected free and fixed in 10% formaldehyde solution. In addition, the thyroids were similarly dissected, weighed, and fixed in formaldehyde, and venous blood was removed from the inferior vena cava. Counting was carried out in a well-type scintillation counter which was precalibrated for ^{131}I , and the final results expressed as the ratio of counts per gram of tissue to counts per milliliter of blood.

Slides of the breast tissue and thyroid gland were prepared and stained with hematoxylin and eosin (H & E). Resulting breast sections stained with H & E were evaluated under high power ($\times 100$) by use of a reticle with concentric circles, 0.5 mm to 12 mm. Mean acinus, duct, and lobule sizes were measured for at least six lobules on each slide. The average evaluation for each group of experimental and control animals was finally expressed as a multiple of the results for the breast of the normal untreated female rat.

Histochemical studies were done to characterize the secretions. These studies included Nile blue sulfate with and without acetone extraction and PAS reagents with and without diastase digestion.

Results

Morphology.—Photomicrographs show the breast tissue of rats in the control (Fig 1) and treated (Fig 2, 3, and 4) groups. The acinar, duct, and lobule areas of the breast tissue sections from the experimental animals were measured. It can be seen

that the changes described for the single-field photomicrographs parallel the objective results reproduced in the Table.

Iodine deficiency (Fig 2) alone produces mild atrophy of the mammary glands. When estrogen is given to iodine-deficient animals, glandular dilatation and mild enhancement of the normal estrogenic ductal effect occurs. In the presence of iodine deficiency, testosterone-treated rats display a marked cellular and cystic hyperplasia of the glands.

Rats treated with propylthiouracil show mild glandular hyperplasia (Fig 3). When propylthiouracil-treated normally fed rats receive estrogen, the breasts show marked ductal dilatation with papillary hyperplasia of the lining, while moderate cystic dilatation and secretion occurs in the glands. The breasts of propylthiouracil-treated rats given testosterone show mild ductal growth with coalescent cystic glands filled with secretion.

When propylthiouracil is administered to iodine-deficient animals (Fig 4), mild ductal hypertrophy with cellular and glandular hyperplasia results. Marked ductal dilatation and papillary hyperplasia of the lining occurs when estrogen is administered to propylthiouracil-treated iodine-deficient animals; their glands show striking dilatation with secretion. In the presence of testosterone, the propylthiouracil-treated iodine-deficient animals display such marked ductal proliferation and glandular dilatation that macrocysts are formed.

Histochemistry.—Preliminary histochemical studies show that the secretions within the cystic areas of the mammary glands contain glycogen, glycoprotein, triglycerides, free fatty acids, and lipoproteins.

Thyroid Evaluation.—The one-hour thyroid to

blood ratios obtained show expected increases in uptake by the iodine-deficient groups and decreases in the propylthiouracil-treated groups. Thyroid gland histology shows those changes from the normal which were anticipated in the altered thyroid states of the experimental method.

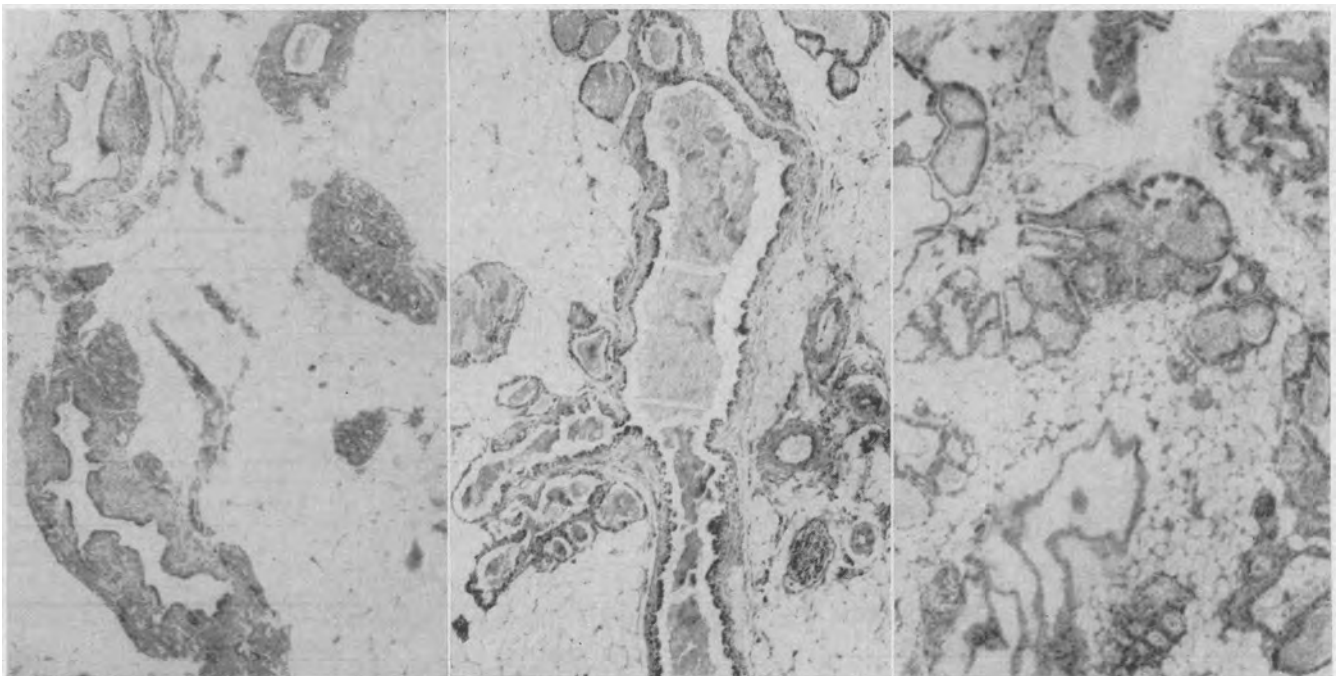
Comment

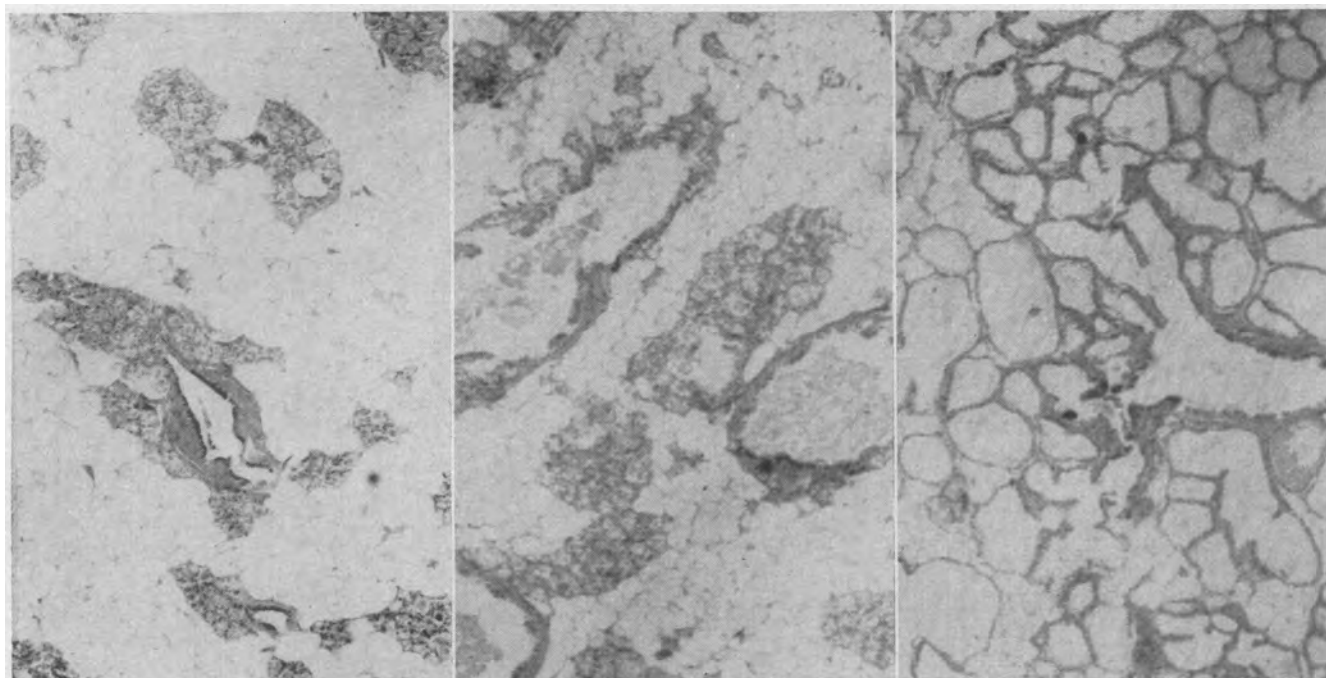
Enhanced development of the mammary glands after thyroidectomy has been demonstrated to occur in both female and male rats.⁷⁻⁹ Thyroidectomy and thiouracil treatment increase the effectiveness of administered estrogens or testosterone by stimulating alveolar development in the rat breast.¹⁰⁻¹² Thiouracil does not itself produce mammary alveolar development, but it enhances the response to administered estrogen.¹³ Changes in mammary gland development and responsiveness in iodine-deficient animals have not been reported to our knowledge.

Our studies show that mild atrophy of the breast occurs with iodine deficiency alone. However, the responses of the breast tissues to sex-hormone treatment are markedly accentuated in the iodine-deficient animals. Of particular interest are the marked proliferative changes seen in the groups of rats receiving testosterone or estrogen while under the combined influence of iodine deficiency and propylthiouracil.

Thyroid abnormalities as a cause of gynecomastia remain controversial. Although cases of gynecomastia with hyperthyroidism and hypothyroidism have been reported, data are generally insufficient to exclude the possibility of fortuitous associations. Most authors are satisfied that the reason for transient gynecomastia in hyperthyroid males treated with

3. Effect of hormones on breast of propylthiouracil-treated rat: Left, No hormones. Center, Estrogen. Right, Testosterone (hematoxylin and eosin, $\times 24$).





4. Effect of hormones on breast of chronically iodine-deficient, propylthiouracil-treated rat: Left, No hormones. Center, Estrogen. Right, Testosterone (hematoxylin and eosin, $\times 24$).

^{131}I is refeeding after malnutrition.¹⁴ Our findings in the breasts of iodine-deficient and/or hypothyroid female rats, particularly those rats treated with an androgen, show both acinar and ductal growth with lobule formation in contrast to the microscopic changes in gynecomastia which show growth of mammary ducts and periductal stroma with absent lobule formation.¹⁵ We are presently determining the effects of iodine in the male breast.

It is generally accepted that carcinoma occurs four times as often in dysplastic breasts as it does in normal breasts.¹⁶ Although evidence for progression from benign dysplasia to malignant neoplasia is lacking, this experimental model may provide a means of studying premalignant changes.

There has been voluminous literature proposing that the incidence of carcinoma of the breast increases in hypothyroidism and is reduced in hyperthyroidism. In a recent series of patients with thyroid disease,⁴ approximately 8% had nonthyroid malignancies. There was a decreased incidence of cancer in the thyrotoxic group as compared with those who were in the euthyroid or myxedematous groups. Daro et al⁵ have noted that a large number of female patients whom they had treated for clinical and subclinical hypothyroidism had associated cystic nodular breasts which improved with thyroid therapy. Wilkins and Morton⁶ have found that, in the presence of metastatic breast adenocarcinoma, the rat thyroid has a tendency to

atrophy and to lose its function.

Since statistical studies in regions of endemic goiter suggest increased mammary carcinoma morbidity,^{1,2} it is interesting to learn that, in a recent investigation by the World Health Organization, even remarkably large sections of North America were considered as endemic goiter areas.³ This problem has persisted despite compulsory iodized table salt. Other continents show even larger goiter belts than those on this continent. Many factors causing endemic goiter are still unknown.

In order to determine whether the changes seen in our study result from the lack of iodine at the breast tissue level or whether a relative reduction in thyroid hormone affects the breast tissue components, the breasts of iodine-deficient animals were compared with breasts of animals made hypothyroid with propylthiouracil. Histological changes clearly showed the difference in the effects of the

Average Sizes of Acini, Ducts, and Lobules in Experimental Groups*

Experimental Group†	Figure	Experimental Condition	Acini‡	Ducts‡	Lobules‡
1	1 (left)	Normal diet	1	1	1
2	1 (center)	Normal diet, estrogen	3	3	4
3	1 (right)	Normal diet, testosterone	4	2	5
4	2 (left)	Iodine-deficient diet	1	0.5	1
5	2 (center)	Iodine-deficient diet, estrogen	2	3.5	6
6	2 (right)	Iodine-deficient diet, testosterone	12	1	8
7	3 (left)	Normal diet, propylthiouracil	4	3.5	6.5
8	3 (center)	Normal diet, propylthiouracil, estrogen	4	5	9
9	3 (right)	Normal diet, propylthiouracil, testosterone	12	2	7
10	4 (left)	Iodine-deficient diet, propylthiouracil	6	3	9
11	4 (center)	Iodine-deficient diet, propylthiouracil, estrogen	8	6	11
12	4 (right)	Iodine-deficient diet, propylthiouracil, testosterone	24	7	34

*Breast tissue was evaluated under high power ($\times 100$) by use of a reticle with concentric circles.

†Number of animals in each group was seven.

‡Results expressed as multiples of breast findings with normal diet as unity.

two conditions on the mammary gland.

We are at present carrying out studies of the changes in the breasts of rats made iodine deficient with a variety of dietary regimens, and comparing these changes with those seen in other altered thyroid states, using histologic and autoradiographic techniques for morphologic study and standard isotopic methods for measuring iodine kinetics.

The major possibility raised by these studies is that while neither thyroid status nor the influence of sex hormones independently affect the breast sufficiently to account for these breast lesions clinically or experimentally, in combination a profound effect is seen.

Summary

Iodine deficiency was found to enhance the response of rat breast tissues to sex-hormone injections; the breast changes seen in the iodine-deficient rat were clearly distinguishable from those induced by sex hormones in the hypothyroid and in the euthyroid rat. Estrogen and testosterone administration to iodine-deficient hypothyroid rats resulted in lesions which mimic human cystic disease of the breast. Thus the present study suggests another physiologic factor which may act to modify breast-sex steroid interactions.

This investigation was supported in part by Public Health Service research grant CA 08615-01 from the National Cancer Institute, and by American Cancer Society institutional grants IN77 and IN77C.

References

1. Desai, P.: Observations cliniques en faveur de l'existence de relations entre la fonction thyroïdienne et al comportement de cancers hétérologues, *Acta Chir Belg* 55:25-49 (Jan) 1956.
2. Bogardus, G.M., and Finley, J.W.: Breast Cancer and Thyroid Disease, *Surgery* 49:461-468 (April) 1961.
3. Kelly, F.C., and Snedden, W.W.: Prevalence and Geographical Distribution of Endemic Goitre, *WHO Monogr Ser* 44:27-233, 1960.
4. Liechty, R.D.; Hodges, R.E.; and Binket, J.: Cancer and Thyroid Function, *JAMA* 183:30-32 (Jan 5) 1963.
5. Daro, A.F.; Gollin, H.A.; and Samos, F.H.: The Effect of Thyroid on Cystic Mastitis, *J Int Coll Surg* 41:58-59 (Jan) 1964.
6. Wilkins, R.H., and Morton, D.L.: The Influence of Thyroid Hormone Analogues on an Isotransplanted Spontaneous Mammary Adenocarcinoma in Mice, *Cancer* 16:558-563 (May) 1963.
7. Wichert, C.K.; Boyd, R.W.; and Cohen, R.S.: A Study of Certain Endocrine Effects on the Mammary Glands of Female Rats, *Anat Rec* 61:21-43 (Dec) 1934.
8. Mixner, J.P., and Turner, C.W.: Influence of Thyroxine Upon Mammary Lobule-Alveolar Growth, *Endocrinology* 31:345-348 (Sept) 1942.
9. Chamorro, A.: Rôle de la Surrénale et de la Thyroïde Dans l'Action des Stéroïdes Mamogènes, *C R Soc Biol* 140:721-722, 1946.
10. Leonard, S.L., and Reece, R.P.: The Relation of the Thyroid to Mammary Gland Growth in the Rat, *Endocrinology* 28:65-69 (Jan) 1941.
11. Smithcors, J.F., and Leonard, S.L.: Relation of Thyroid to Mammary Gland Structure in the Rat With Special Reference to the Male, *Endocrinology* 31:454-460 (Oct) 1942.
12. Trentin, J.J.; Hurst, V.; and Turner, C.W.: Thiouracil and Mammary Growth, *Proc Soc Exp Biol Med* 67:461-464 (April) 1948.
13. Smithcors, J.F.: Effects of Thiouracil on the Mammary Gland, *Proc Soc Exp Biol Med* 59:197-200 (Jan) 1945.
14. Stokes, J.F.: Unexpected Gynecomastia, *Lancet* 2:911-913 (Nov 3) 1962.
15. Hall, P.F.: *Gynecomastia*, Monographs of the Federal Council of the British Medical Association in Australia, Sydney: Australian Medical Publishing Co., No. 2, 1959.
16. Ingleby, H., and Gershon-Cohen, J.: *Comparative Anatomy, Pathology and Roentgenology of the Breast*, Philadelphia: University of Pennsylvania Press, 1960.

A BRIEF HISTORY OF SCHOLARLY PUBLISHING.—

- 1483 Invention of *ibid*.
- 1507 First use of the circumlocution.
- 1859 "Without whom" is used for first time in list of acknowledgments.
- 1888 Martyrdom of Ralph Thwaites, an author who deletes 503 commas from his galleys and is stoned by a copy-editor.
- 1901 First free desk copy distributed. (Known as Black Thursday.)
- 1928 Early use of the ambiguous rejection letter, beginning, "While we have many good things to say about your manuscript, we feel that we are not now in a position. . . ."
- 1934 Bookstore sends for two copies of Gleep's *Origin of Leases* from university press, and instead receives three copies of Darwin's *Storage of Fleeces* plus half of stale peanut butter sandwich from stockroom clerk's lunch. Beginning of famous Brentano Rebellion, resulting in temporary improvement in shipping practices.
- 1952 Scholarly writing begins to pay. Professor Harley Biddle's publishing contract provides for royalty on his book after 1,000 copies have been sold to defray printing costs. Total sales: 1,009 copies.
- 1961 Important case of *Dulany v. McDaniel*, in which Judge Kelley rules that to call a doctoral dissertation a nonbook is libelous per se.—Jackson, D.: A Brief History of Scholarly Publishing, *Scholarly Books in America* 3:2 (May-July) 1961.