1951 USA
DL 8/29/2018

RADIOIODINE PENETRATION THROUGH INTACT ENAMEL WITH UPTAKE BY BLOODSTREAM AND THYROID GLAND

HERBERT J. BARTELSTONE, D.D.S.*

Veterans Administration Hospital, Bronx, N. Y. and College of Physicians and Surgeons, Columbia University, New York, N. Y.

INVESTIGATIONS conducted to determine whether substances will penetrate enamel centripetally have resulted in conflicting reports (Fish[1] and Berggren[2]) as to whether large dye molecules and silver nitrate and other reagents can penetrate enamel from its surface (centripetal penetration). Centrifugal penetration of dyes into enamel (from the pulpal side) has also been described. Definitive evidence of rapid dye penetration through enamel in either direction is not available. Centripetal experiments (Atkinson[3]) indicate salts penetrate the enamel of extracted teeth. Wainright and Lemoine[4] showed centripetal penetration of radiocarbon-labelled urea through intact enamel of extracted teeth. The possibility of differences in permeability of extracted teeth as opposed to teeth in situ has been reported by Bodecker and Lefkowitz.[6]

centripetal = through surface into pulp

Berggren,[2] using in vivo methods, demonstrated centripetal penetration of P-32 and tetanus toxin through enamel. Mandel and Sarkady[5] administered large doses of sodium iodide to cats and showed some evidence of penetration of the iodide into the enamel and dentin. Bartelstone and co-workers,[7, 8] demonstrated radioautographic evidence of penetration of I-131 into enamel in cats and human beings following systemic administration of the isotope.

This study was undertaken to determine whether I-131 applied to the intact surface of enamel would penetrate through the enamel and dentin and concentrate in the thyroid gland of cats.

METHOD

Eight adult male cats, each weighing 6 to 8 pounds, were used. The animals were maintained under Nembutal anesthesia throughout the experiment.

A wax block was prepared by folding together warmed sheets of dental base plate wax (Fig. 1). The size of the wax block prevented movement of the mandible. Two aluminum shells were inserted into the dorsal surface of the wax block, the distance between the center of the shells equalling the interval between the maxillary canines.

A solution (0.5 ml.) containing about 500 microcuries of carrier-free I-131, in the form of NaI, was placed in each shell. The teeth were wiped with surgical sponges and the wax block placed between the jaws (Fig. 1) in such

Reviewed in the Veterans Administration and published with the approval of the Chief Medical Director. The statements and conclusions published by the author are the result of his own study and do not necessarily reflect the opinion or policy of the Veterans Administration.

Presented to the New York Section of the International Association for Dental Research, Nov. 9, 1950, and the Dentistry Section at the 117th meeting of the American Association for the Advancement of Science, Cleveland, Ohio, Dec. 3, 1950.

Received for publication, March 13, 1951.

*Present address: National Institute of Dental Health Unit, U.S.P.H.S. Hospital, Staten Island, N. Y.

a manner that only the tips of the teeth were dipped and retained in the solution. When the maxillary canines were used as experimental teeth, the mandibular canines acted as controls. The cat was placed on a lead plate, 1 inch thick, and its head surrounded by lead blocks. A portable shielded Geiger counter was fixed at the level of the thyroid cartilage. To reduce the background count because of the I-131 source in the mouth, lead sheets were positioned immediately inferior to the mandible. The counting rate over the thyroid gland was determined to establish the background as a zero point at the start of the experiment. The experiment was continued until significant counts, above the background, were noted.

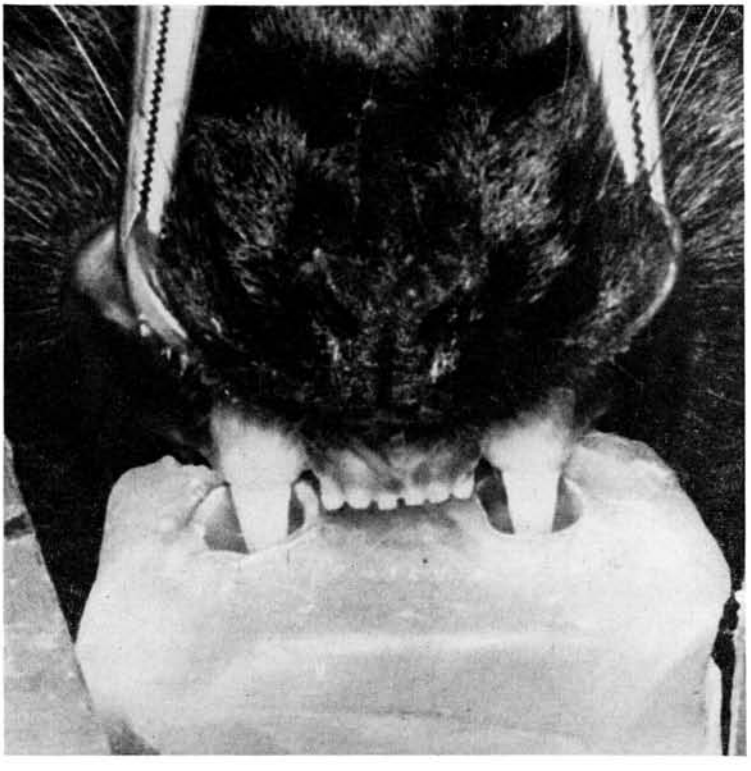

Fig. 1.—Tip of canines of anesthetized cat dipping into crucibles containing 0.5 ml. NaI-131 (500 microcuries). Note that rubber dam although normally in position isolating canines, has, in this case, been removed for photographic purposes.

The animals were sacrificed and longitudinal slices, in a sagittal plane, were cut from the four canines and the supporting tissue of each. Tooth sections were ground to seventy-five micra under oil (oil reduces leaching of I-131),[7] and buffed and polished until free of contaminated grinding debris. Frozen sections of the thyroid glands were prepared.

Radioautographs were made from the tooth and thyroid sections on Kodak contrast lantern slide plates and No-Screen x-ray film. Exposure was estimated by Geiger counter surveys, assuming uniform distribution of I-131 as well as uniform self-absorption of sections.

RESULTS

Activity over the thyroid gland after 1.5 to 2 hours as demonstrated by Geiger counter and radioautographs was evidenced in all cases.

Centripetal penetration of I-131 into the tooth is shown in the radioautograph (Fig. 2). The distribution pattern indicates a diffuse penetration of I-131 through enamel with a concentration of radioiodine at the dentino-enamel junction. Dentin is diffusely penetrated and I-131 is found in the pulp (Figs. 2*B*, and 3*B*).

There is radioautographic evidence (Fig. 2, *B*) of distribution of I-131 in cementum, periodontal membrane, alveolar bone and marginal gingiva. In the radioautograph illustrated (Fig. 2, *B*) there is no evidence of I-131 distributed on that portion of the enamel surface which was not actually dipped into the source solution.

No evidence of I-131 uptake was found in any of the control sections.

DISCUSSION

Radioiodine was chosen as the tracer substance because it has been found useful for studying the distribution of tissue fluid solutes in teeth of human beings and cats.[7, 8] A relatively high concentration of I-131 is found in saliva following systemic administration.[8]

The method devised for this experiment has several advantages over previous methods for applying reagents to teeth. It may be used for both centripetal or centrifugal studies of enamel permeability. The external environment of the expermental tooth can be controlled, permitting variation in the type of fluid, temperature, and level of immersion. No time limit is imposed by this method. The introduction of variables, such as cavity preparations and cements or waxes, are not required to keep the reagent in contact with the tooth.

There was no evidence of surface spread of I-131 beyond the level of the solution. The bare area corresponding to the enamel surface seen in Fig. 2, *B* demonstrates this point. It may therefore be deduced that distribution in the periodontium is not due to any external bridge between the I-131 source and the mucous membrane.

Survey radioautographs were used. Although automatically superimposed autographs and sections would be preferable, the tooth sections were too thick to permit collimation of radiation to a degree commensurate with microscopic observation at high power. Because these ground sections were unmounted, a variation from the conventional survey radioautographic technique was employed. The sections were placed between two emulsions varying in sensitivity to radiation. One exposure produced two radioautographs clearly visualizing areas of low uptake on the fast emulsion and areas of high uptake on the slower emulsion.

By using the thyroid gland as an indicator, the systemic uptake of I-131 was demonstrated earlier than if the blood had been counted. If the experimental time interval had been extended to obtain detectable concentration of I-131 in the blood, the control teeth would have given positive radioautographs.

This would have made it impossible to study the I-131 distribution patterns through the tooth and periodontium as a function of the source external to the enamel surface.

The radioautographs of the tooth sections may be considered analagous to the dynamic interpretation of candid photography of moving objects. The distribution patterns demonstrate the penetration through the tooth of I-131 "stopped" at a given point in time as it proceeds toward the pulpal tissue from the surface. No detectable changes in the distribution of the I-131 were found in successive radioautographs made from the sections indicating that I-131 did not shift in the tooth after sectioning.

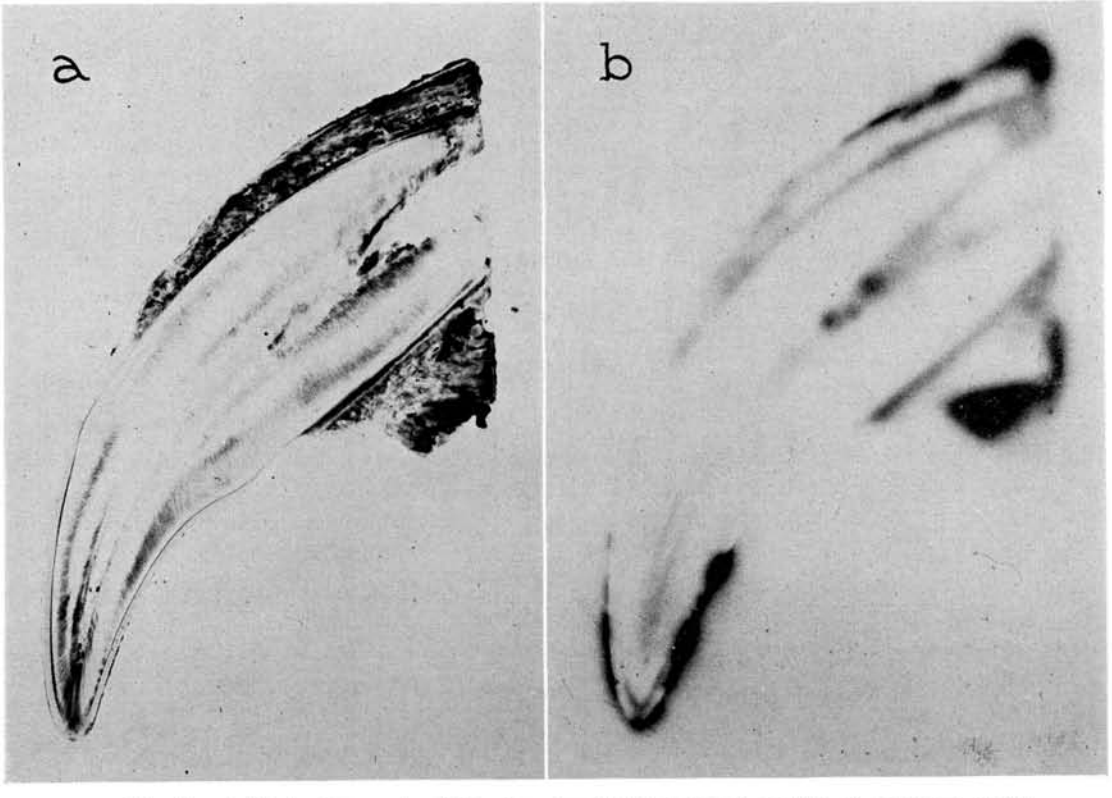

Fig. 2.—*A*, Photomicrograph of 75 micra longitudinal ground section of cat lower canine (experimental). *B*, Radioautograph made from section in *A* on Kodak contrast plate. Distribution of I-131 through enamel and into dentin. Uptake by cementum, periodontal membrane, alveolar bone, and gingiva. Absence of I-131 contamination on enamel surface, apically, beyond level of solution.

In I-131 studies previously reported,[7, 8] in which the iodide was administered systemically, uptake was obtained in the cementum, bone, and connective tissue of the periodontium. Under conditions imposed by the present experiment, however, the distribution pattern in the periodontium is considered significant because the evidence indicates a pathway, other than systemic approach, for penetration of a tissue fluid solute into the periodontium by way of the tooth. The degree to which this pathway of entrance may influence the periodontium remains to be determined.

Fig. 4 suggests that some of the I-131 enters the periodontal membrane after leaving the pulp, and reaches the alveolar bone and cementum. However, upon leaving the pulp, the I-131 may enter the bone at the apex of the root of the tooth, and after distribution in the bone, reach the periodontal membrane, cementum, and gingiva. The lateral spread of I-131 along the dentino-enamel junction does not appear to be a pathway to the periodontium under the conditions of the experiment.

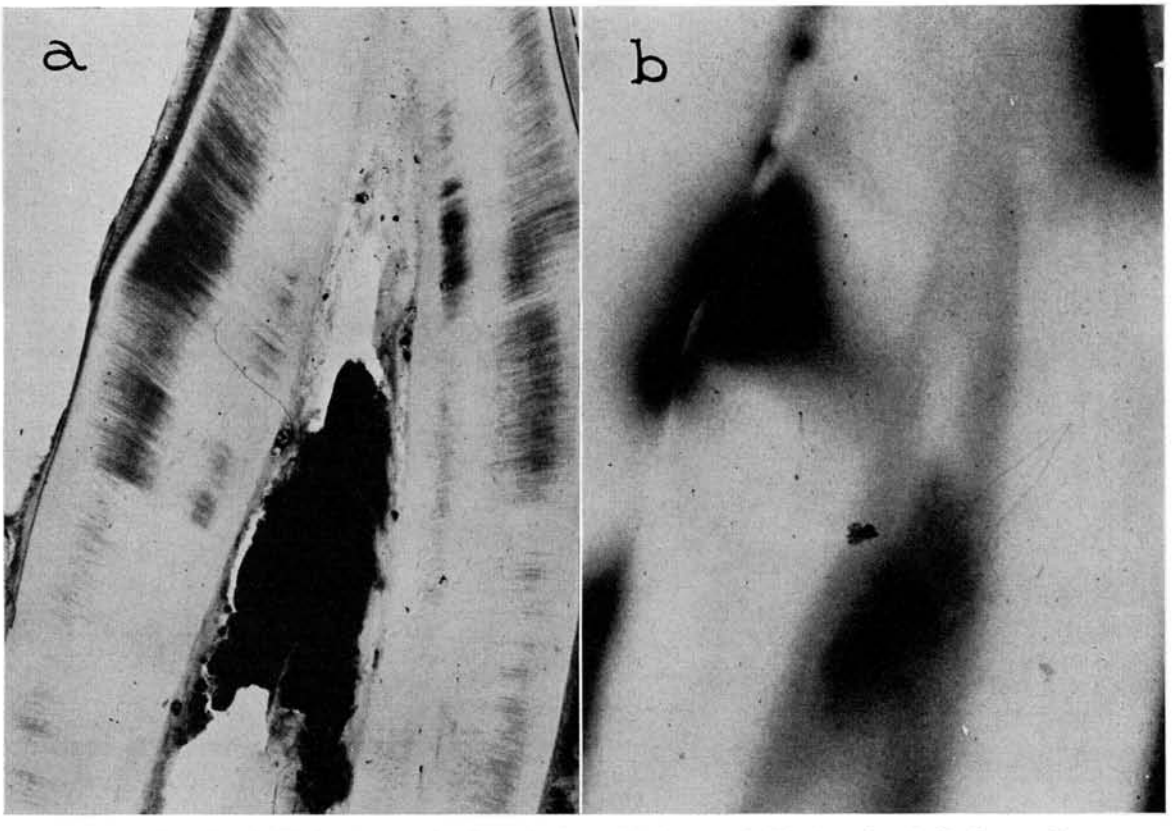

Fig. 3.—*A*, Photomicrograph of cervical one-third area of 75 micra longitudinal ground section of cat upper canine (experimental). Note darkened tubules in dentin, presence of some pulp tissue. *B*, Radio-autograph made from section in *A* on Kodak contrast plate. Diffuse penetration through enamel and dentin, extending into pulp.

SUMMARY

A solution (0.5 ml.), containing 500 microcuries of carrier-free I-131 as NaI-131, was applied to the external surface of intact enamel of eight animals. Significant counts were observed over the thyroid gland, indicating penetration of I-131 through enamel and dentin and thus into the pulp and the blood-stream. Radioautographs demonstrate diffuse penetration of I-131 through enamel and dentin and uptake by the periodontal tissues.

Grateful acknowledgment is extended to Drs. Bernard Roswit and Rosalyn Yalow of the Veterans Administration and Dr. Barnet Levy of Columbia University for their cooperation

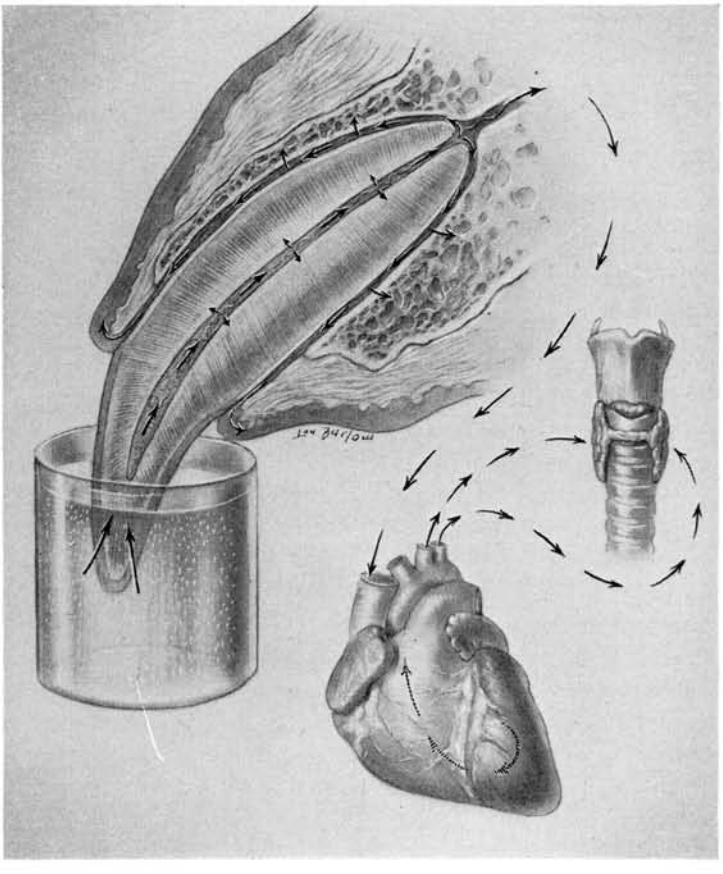

Fig. 4.—Penetration on I-131 from source in crucible, through intact enamel and dentin into the pulp and periodontium. Uptake of I-131 by bloodstream with concentration in thyroid gland.

and advice; to Mr. Martin Jachter and Mrs. Katherine Newerby for technical assistance, and to Mr. Sidney Shapiro and Mr. Lou Barlow of the Medical Illustration Department of the Veterans Administration.

REFERENCES

1. Fish, E. W.: An Experimental Investigation of Enamel, Dentine and the Dental Pulp, London, 1933, John Bale & Sons and Danielsson, Ltd.
2. Berggren, H.: Permeability of Enamel and Dentin, 40. No. 1B. Svensk Tandlakaretidskrift, 1947.
3. Atkinson, H. F.: An Investigation Into the Permeability of Human Enamel Using Osmotic Methods, *Brit. D. J.* **83**: 205, 1947.
4. Wainwright, W. W., and Lemoine, F. A.: Rapid Diffuse Penetration of Intact Enamel and Dentin by Carbon Labeled Urea, *J. A. D. A.* **41**: 135, 1950.
5. Mandel, I. D., and Sarkady, L.: Introduction of Sodium Iodide Into the Calcified Dental Tissues, *J. D. Res.* **25**: 95, 1946.
6. Bodecker, C. F., and Lefkowitz, W.: Concerning the Vitality of the Calcified Dental Tissues, *J. D. Res.* **16**: 463, 1937.
7. Bartelstone, H. J., Mandel, I. D., Oshry, E., and Seidlin, S. M.: Use of Radioactive Iodine as a Tracer in the Study of the Physiology of Teeth, *Science* **106**: 132, 1947.
8. Bartelstone, H. J.: Survey of the Use of Radioactive Isotopes in Dentistry, *New York J. Dent.* **8**: 320, 1950.

Bartelstone, H. J.: Use of Radioactive Iodine as a Tracer in the Study of the Physiology of Teeth (II), *J. D. Res.* **28**: 658, 1949.

Bartelstone, H. J.: In Vivo Study of the Uptake of Radioactive Iodine by Human Teeth (III), *J. D. Res.* **29**: 684, 1950.