

Fibrosing Alopecia in a Pattern Distribution

Patterned Lichen Planopilaris or Androgenetic Alopecia With a Lichenoid Tissue Reaction Pattern?

Martin S. Zinkernagel, Cand Med; Ralph M. Trüeb, MD

Background: Androgenetic alopecia is characterized by a defined area of progressive nonscarring alopecia. The clinical and histological findings in 15 women and 4 men with progressive scarring alopecia in a pattern distribution were studied. The results were evaluated and compared with clinicopathologic entities that feature scarring of the central scalp area, specifically, lichen planopilaris, pseudopelade, and follicular degeneration syndrome.

Observations: Patients developed progressive fibrosing alopecia of the central scalp, without the multifocal areas of involvement typical of lichen planopilaris and pseudopelade. Perifollicular erythema, follicular keratosis, and loss of follicular orifices were limited to a patterned area of involvement. Biopsy specimens of early lesions demonstrated hair follicle miniaturization and a

lichenoid inflammatory infiltrate targeting the upper follicle region. Advanced lesions showed perifollicular lamellar fibrosis and completely fibrosed follicular tracts indistinguishable from end-stage lichen planopilaris, pseudopelade, or follicular degeneration syndrome.

Conclusions: Some patients with androgenetic alopecia might have additional clinical and histological features of inflammation and fibrosis limited to the area of androgenetic hair loss. In these patients, the histological findings of early lesions are identical to those seen in lichen planopilaris. The lichenoid tissue reaction leading to follicular destruction in these patients might be pathogenetically related to the events underlying androgenetic alopecia.

Arch Dermatol. 2000;136:205-211

ALOPECIA IN a pattern distribution is a common event associated with androgenetic hair loss and aging. Although it is regarded as a pathologic process by some physicians and many affected patients, by others it is considered a genetically determined physiologic event in the lives of most men and women. The same controversy applies to the histological finding of inflammatory cells in the vicinity of the upper hair follicle in androgenetic alopecia (AGA)^{1,2} inasmuch as it remains uncertain whether this phenomenon is still a physiologic event or already reflects a pathologic process. Clinically, AGA is usually a noninflammatory and nonscarring process³ that eventually leads to permanent hair loss of the affected scalp.

*For editorial comment
see page 235*

We present our observations on 19 patients (15 women and 4 men) who developed progressive fibrosing alopecia in

a pattern distribution (FAPD). In all patients, the histopathologic findings showed features of AGA and lichen planopilaris.

RESULTS

CLINICAL DATA

The case histories of 19 patients aged 35 to 74 years (mean, 59 years)—15 women (age range, 48-74 years; mean age, 60 years) and 4 men (age range, 35-71 years; mean age, 54 years)—were reviewed. Demographic and clinical data from all patients are summarized in **Table 1**. Seven patients (37%) complained of symptomatic (pruritus or pain) and all patients of accelerated hair loss in a female or male pattern distribution, respectively. The scalp showed perifollicular erythema in all patients, loss of follicular orifices in 15 (79%), and follicular keratosis in 11 (58%) limited to the area of androgenetic hair loss (**Figures 1, 2, 3, and 4**). Multifocal areas of alopecia typical of lichen planopilaris and lichen planus-type lesions on areas other than the scalp were

From the Department of Dermatology, University Hospital of Zurich, Zurich, Switzerland.

PATIENTS, MATERIALS, AND METHODS

Between April 1, 1991, and December 31, 1998, 15 women and 4 men were referred to the Department of Dermatology, University Hospital of Zurich, Zurich, Switzerland, for evaluation of progressive scarring alopecia in a pattern distribution (female and male pattern AGA). In addition to the clinical data, a hair pluck test was performed in 4 patients and lesional scalp biopsy specimens were obtained from 14 patients for routine histological examination. Fresh tissue samples obtained from 6 patients were snap frozen for direct immunofluorescence studies. Routine laboratory investigations included C-reactive protein, serum ferritin, and basal thyroid-stimulating hormone levels; syphilis serologic tests (Venereal Disease Research Laboratory and treponema pallidum hemagglutination); and antinuclear factor levels. Sex hormone levels (follicle-stimulating hormone, luteinizing hormone, prolactin, estradiol, testosterone, dehydroepiandrosterone sulfate, sex hormone-binding globulin, and free testosterone) were evaluated in 3 women.

absent. Two patients (1 woman and 1 man) showed frontal fibrosing alopecia-type changes in addition to the lichenoid changes confined to the area of AGA, ie, frontal recession extending to the marginal temporal and parietal areas of the scalp associated with scarring (Figure 4). In one woman, the vertex region showed a defined area of hair loss as seen in male pattern AGA of the Hamilton-Norwood type III vertex. Frontal hair plucks (trichograms) performed in 4 patients demonstrated an increased number of telogen hairs in 3 patients (43%, 40%, and 27%; reference range, 12%-15%; maximum, 20%⁴) and correspondingly a significant reduction of the anagen-telogen hair ratio (1.3, 1.1, and 1.6; reference value, minimum of 4.0) in 3 patients. Results of laboratory investigations—including complete blood cell counts; basal thyroid-stimulating hormone, C-reactive protein, and serum ferritin levels; and testing for syphilis—were normal in all patients. Of serum samples from 6 patients tested for antinuclear antibodies, 3 showed positive results at a titer of less than 1:80. Serum androgen levels in 3 women tested were normal. Four postmenopausal women were receiving estrogen substitution therapy, and in 2 it was combined with norethindrone acetate administration. One 55-year-old man was taking oral testosterone undecanoate regularly. Three patients were undergoing antihypertensive therapy (enalapril maleate, atenolol, amiloride hydrochloride, hydrochlorothiazide, and quinapril hydrochloride), and 1 patient was taking nonsteroidal anti-inflammatory drugs (aspirin) regularly. Two patients had diabetes mellitus and were taking insulin and metformin. Except for preandrogenic gestagen and androgen therapy, no link between drug intake and progression of alopecia was apparent on the basis of the patient history.

CLINICAL COURSE AND MANAGEMENT

Androgenetic hair loss in all 19 patients initially had been slowly progressive, with an eventually accelerated course in the area of scarring alopecia. No single treatment option, except antiandrogen treatment in 2 women and finasteride treatment in a man, significantly altered the course of the disorder. In the 2 women receiving hormonal replacement therapy with a partially androgenic effect, norethindrone was substituted with 1 mg of cyproterone acetate. Similar to other patients in the study, both additionally received topical 5% minoxidil and clobetasol propionate. This therapeutic regimen seemed to decrease active hair loss and clinical signs of inflammation. In one woman, antiandrogenic therapy with 10 mg of cyproterone as a single treatment agent also stabilized the progression of disease, but this treatment was discontinued because of gynecologic problems, with recurrence of follicular inflammation and hair loss. In the man treated with oral finasteride, 1 mg daily, further hair loss was halted, as evidenced by normalized frontal telogen hair counts and anagen-telogen hair ratios in the trichogram after 6 months of treatment (before treatment: telogen hair count, 43%; anagen-telogen hair ratio, 1.3; after treatment: telogen hair count, 10%; anagen-telogen hair ratio, 8.8). Moreover, clinical signs of inflammation were reduced with finasteride treatment. In other patients, practically serving as a control group, treatment with topical preparations such as highly potent (betamethasone valerate and clobetasol) or moderately potent (mometasone furoate) corticosteroids produced only symptomatic relief of pruritus. Six patients received topical 0.1% tretinoin lotion without any evident benefit. Use of antimalarial medication by one patient had no effect on disease progression.

HISTOPATHOLOGIC FINDINGS

Lesional scalp biopsy specimens taken from 14 patients demonstrated similar pathological changes. Histological features of the patients studied are summarized in **Table 2**.

Terminal hair follicles were significantly reduced in number through miniaturization to vellus hair follicles in 10 patients (71%) or replacement by fibrous tracts. A lymphohistiocytic infiltrate was present around the isthmus and infundibular region of the hair follicles in all 14 patients, with a follicular interface dermatitis pattern in 8 (57%), whereas the overlying interfollicular epidermis and lower portions of the follicles including the hair bulbs were spared (**Figure 5**). This was associated with concentric perifollicular lamellar fibrosis in 13 (93%) of 14 patients, which was better displayed on horizontal sections (**Figure 6**). The external root sheaths showed focal liquefaction degeneration of the basal cell layer and prominent apoptosis of follicular keratinocytes in 4 patients (29%). Follicular infundibuli harboured numerous *Demodex folliculorum* organisms in 2 patients with severe inflammatory alopecia and *Pityrosporum ovale* organisms in an additional patient. No inflammation or fibrosis was seen around the sweat glands. Besides replacement by fibrous tracts in the subcutis that extended

Table 1. Demographic and Clinical Data From 19 Patients With Fibrosing Alopecia in a Pattern Distribution*

Patient No./ Sex/Age, y	Age at Onset of Clinical AGA, y	Family History of AGA	Type of AGA	Scalp Dysesthesia (Pruritus or Pain)	Follicular Keratosis	Loss of Follicular Orifices
1/F/68	66	Yes	L I	Yes	Yes	Yes
2/M/55	NA	Yes	HN IV	Yes	Yes	Yes
3/F/71	NA	NA	HN III vertex	No	No	Yes
4/M/57	NA	No	HN IV	No	No	Yes
5/F/48	46	No	HN Va	No	No	No
6/M/71	NA	NA	HN IIIa/PFFA	Yes	Yes	Yes
7/F/74	68	No	L II	Yes	Yes	Yes
8/F/59	55	NA	L II	No	No	Yes
9/F/54	50	Yes	L II	No	Yes	Yes
10/F/68	NA	Yes	HN VII	No	No	Yes
11/F/67	63	Yes	L III	Yes	Yes	Yes
12/M/35	21	Yes	L III	Yes	Yes	No
13/F/57	NA	NA	L III/PFFA	No	Yes	Yes
14/F/57	37	No	L III	No	Yes	Yes
15/F/53	NA	No	L III	No	No	Yes
16/F/52	NA	Yes	L II	No	No	No
17/F/53	48	Yes	L II	No	Yes	Yes
18/F/54	37	Yes	L I	No	No	No
19/F/59	NA	NA	L III	Yes	Yes	Yes

*The scalp showed perifollicular erythema in all patients. AGA indicates androgenic alopecia; L, Ludwig; HN, Hamilton-Norwood pattern; PFFA, progressive frontal fibrosing alopecia; and NA, not available.

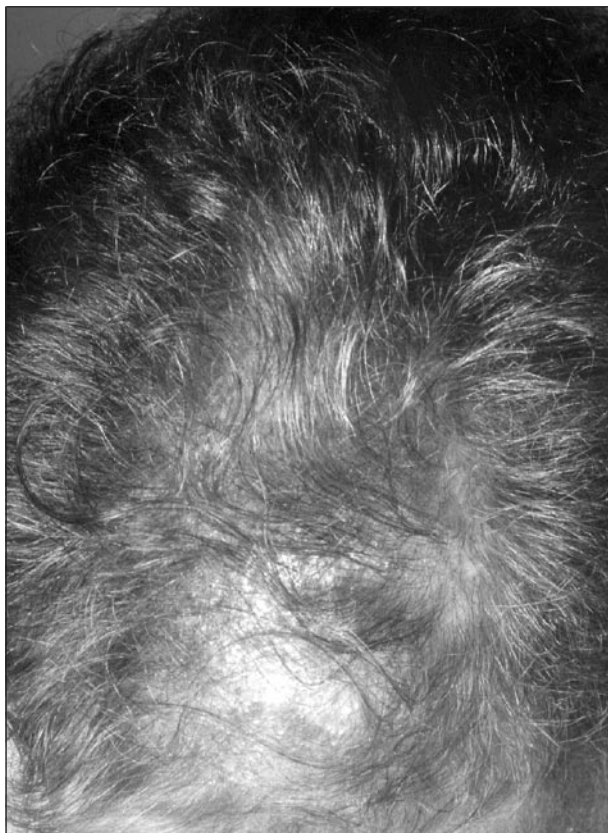

Figure 1. Patient 7. Thinning of the centroparietal scalp hair associated with acuminated follicular lesions.

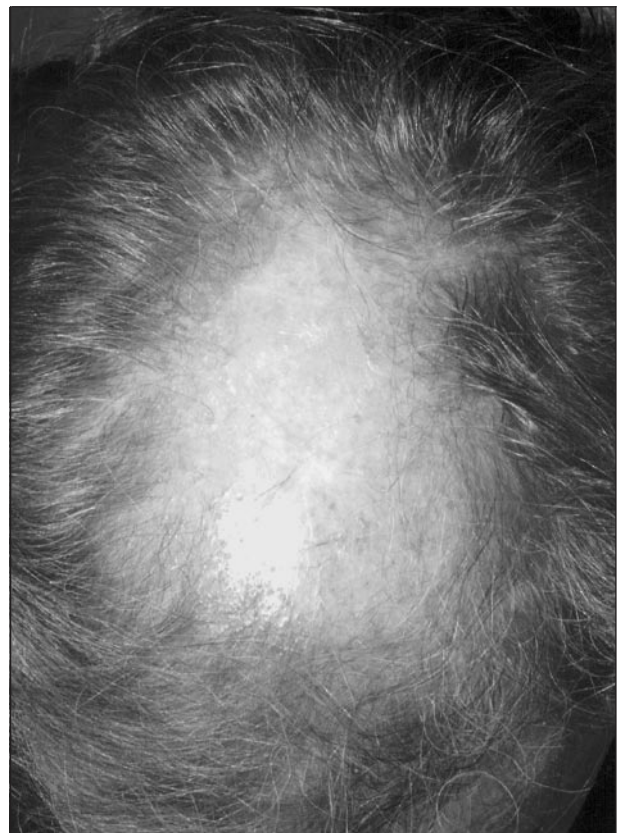

Figure 2. Patient 11. Centroparietal alopecia associated with perifollicular erythema and follicular keratosis.

through the reticular dermis at the sites of destroyed follicles, naked hair shaft fragments occasionally were found loose in the dermis surrounded by a foreign body granulomatous reaction and fibrosis. Also, orphaned ar-

rector pili muscles were found at the sites of destroyed follicles.

Direct immunofluorescence studies performed on 6 biopsy samples revealed only minimal granular staining

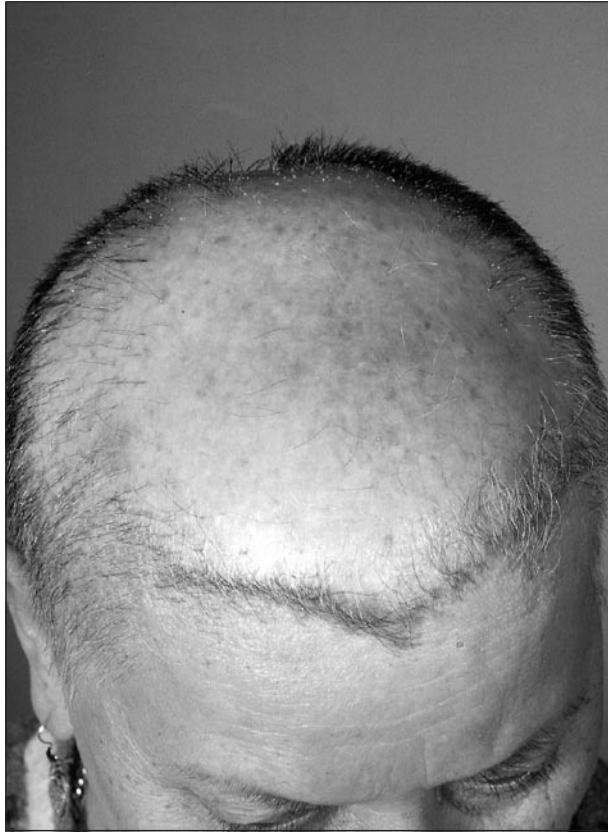


Figure 3. Patient 14. Advanced scarring alopecia of the centroparietal scalp associated with loss of follicular orifices and a remaining frontal hairline.

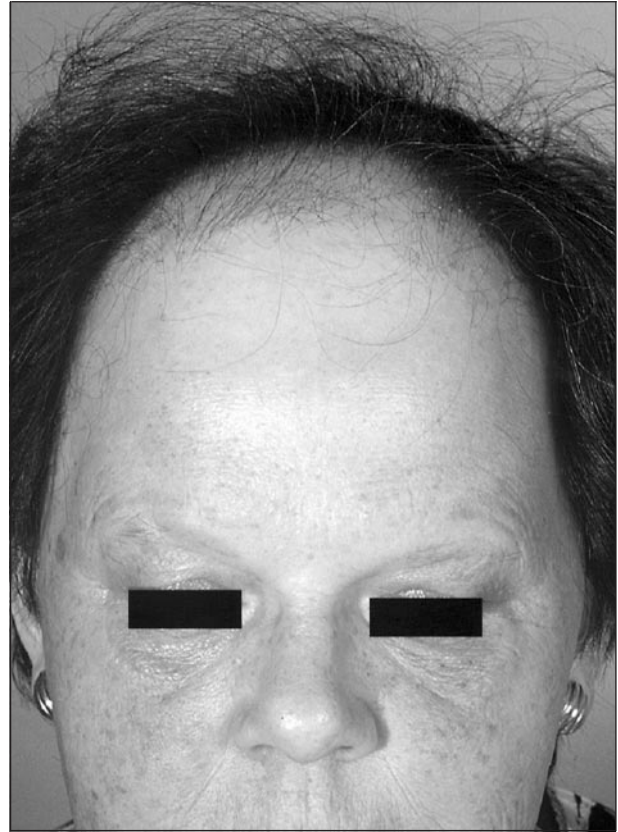


Figure 4. Patient 13. Overlap with frontal fibrosing alopecia.

Table 2. Histological Features of Lesional Scalp Biopsy Samples From 14 Patients With Fibrosing Alopecia in a Pattern Distribution*

Patient No.	Perifollicular Lymphocytic Infiltrate	Perifollicular Lamellar Fibrosis	Follicular Interface Dermatitis	Follicular Keratinocyte Apoptosis	Hair Follicle Miniaturization
1	Moderate	Yes	Yes	Yes	Yes
2	Yes	Yes	Yes	No	Yes
3	Yes	Yes	Yes	Yes	No
4	Yes	Yes	No	No	No
7	Moderate	No	No	No	Yes
8	Yes	Yes	No	No	Yes
9	Yes	Yes	Yes	No	Yes
11	Yes	Yes	Yes	Yes	Yes
12	Yes	Yes	No	No	Yes
13	Yes	Yes	Yes	No	Yes
14	Yes	Yes	No	No	No
15	Yes	Yes	Yes	Yes	No
17	Moderate	Yes	No	No	Yes
18	Yes	Yes	Yes	No	Yes

*Interfollicular interface dermatitis was not present in our patients.

for IgA, IgG, and IgM at the basement membrane zone of approximately one third of samples.

COMMENT

The development of baldness with AGA is associated with androgen-dependent, progressive miniaturization of hair follicles in certain areas of the scalp in genetically predisposed individuals.⁵ Thinning scalp hair grows in a

shorter period and consequently with an increase in the proportion of telogen hairs, which might be detected in trichograms of the frontovertical region.⁴ The histopathologic changes of AGA reflect the pathogenesis of the condition and show miniaturization of the hair follicles corresponding to the progressive shortening of the hair growth cycle.² Whereas a mild, perifollicular, lymphohistiocytic infiltrate, usually around upper follicles, is present in one third of patients with AGA and controls, a

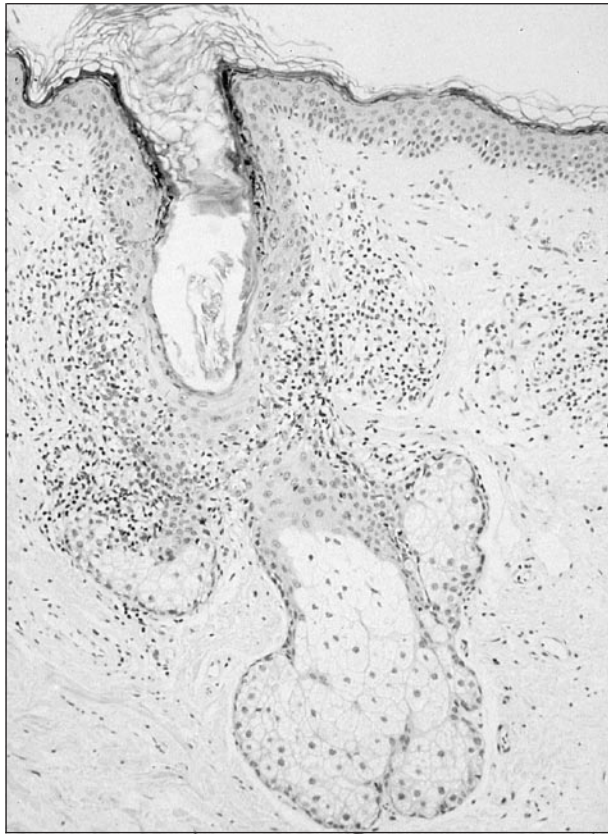


Figure 5. Scalp biopsy specimen of an early lesion demonstrates a lichenoid lymphocytic inflammation targeting the upper portion of the miniaturized hair follicle with focal liquefaction degeneration of the outer root sheath and sparing of the interfollicular epidermis. The dilated infundibulum harbours *Demodex folliculorum* organisms (hematoxylin-eosin, original magnification $\times 125$).

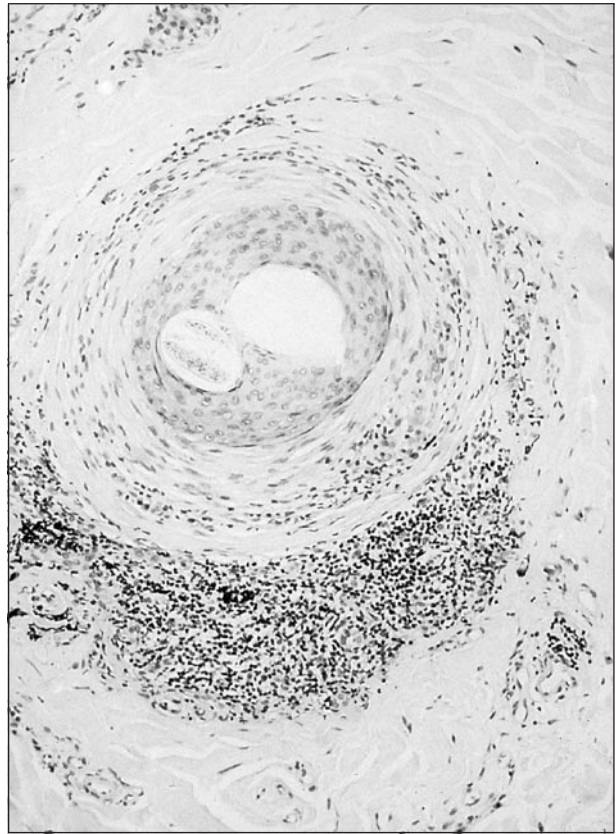


Figure 6. Horizontal section of a scalp biopsy specimen of advanced lesions demonstrates perfollicular lamellar fibrosis associated with lymphocytic inflammation at the isthmus level of the follicle. At this stage, the histological features are indistinguishable from those of pseudopelade and follicular degeneration syndrome (hematoxylin-eosin, original magnification $\times 125$).

moderate to severe, predominantly lymphocytic inflammation associated with loose perfollicular lamellar fibrosis is present in 36% of patients with AGA vs only 10% of controls.² The significance of this inflammatory infiltrate and fibrosis in AGA remains uncertain, and this problem is particularly evident in the differential diagnosis of permanent forms of alopecia, in which the dermatopathologist is confronted with the difficulty of evaluating the role of inflammatory cells visible in the vicinity of otherwise intact-appearing hair follicles.

Our 19 patients displayed progressive scarring alopecia in a pattern distribution. Close clinical examination revealed obliteration of follicular orifices in 15 patients (79%), perfollicular erythema in 19 (100%), and follicular keratosis in 11 (58%) limited to the area of androgenetic hair loss. In 3 of 4 patients in whom trichograms were performed, there was evidence of active AGA, with an increase in the proportion of telogen hairs detected in the frontal region. Histological findings of AGA, ie, increased numbers of miniaturized hair follicles with underlying fibrous streamers, were evident in 10 patients (71%) and were associated with a perfollicular lymphocytic infiltrate in all patients. A pattern of follicular interface dermatitis targeting the upper follicle in 8 patients (57%) represented early lesions, whereas perfollicular lamellar fibrosis in 13 patients (93%) and the presence of selectively fibrosed follicular tracts corresponded to late lesions.

Several conditions might need to be considered in the differential diagnosis of FAPD. The histopathologic features of lymphocytic inflammation involving the upper follicle and the presence of completely fibrosed follicular tracts are those shared by lichen planopilaris, pseudopelade of Brocq, follicular degeneration syndrome, and the more recently described postmenopausal frontal fibrosing alopecia.

Alopecia of lichen planopilaris and pseudopelade of Brocq is similarly insidious and predominantly affects the vertex and parietal areas of the scalp. In contrast, both present with irregular, multifocal areas of scarring alopecia.⁶⁻⁸ Whereas in active lichen planopilaris of the scalp acuminate follicular lesions with perfollicular erythema and follicular keratotic plugs are observed at the margins of the bald areas, inflammation is less obvious in pseudopelade of Brocq.^{9,10} Moreover, lichen planopilaris presents typical lesions of lichen planus on the glabrous skin or mucous membranes in up to 50% of patients.⁷ Pseudopelade of Brocq shares many clinical and histological features with end-stage lichen planopilaris, but there is continued debate about whether it represents a distinct entity or a variant of lichen planopilaris.^{11,12}

The histological findings of advanced lesions in our patients share features with the recently described follicular degeneration syndrome observed in black patients.^{13,14} Also, the clinical presentation of these black women might mimic female pattern AGA because it pro-

duces frontovertical alopecia.¹³ The earliest observable histological abnormalities considered distinctive of this disorder are premature degeneration of the inner root sheath and migration of the hair shaft through the outer root sheath,¹³ whereas the follicular interface dermatitis present in most of our patients is not a feature. On the other hand, we did not demonstrate premature degeneration of the inner root sheath in our patients. Prominent perifollicular fibrosis and lymphocytic inflammation at the level of the isthmus are common features of follicular degeneration syndrome and FAPD and can also be found in other forms of scarring alopecia, including lichen planopilaris and pseudopelade of Brocq, representing an unspecific common final pathway leading to follicular disintegration.

The pattern distribution and histological findings in our patients share features with the recently described¹⁵ progressive frontal fibrosing alopecia observed in postmenopausal women. The clinical presentation in these women might mimic male pattern AGA because it produces frontal recession of the hairline, but it is associated with clinical evidence of scarring. Kossard et al¹⁶ proposed the term *postmenopausal frontal fibrosing alopecia* for this presentation and more recently interpreted this type of alopecia as a frontal variant of lichen planopilaris on the basis of histopathologic and immunohistochemical studies. Considerable overlap exists among postmenopausal frontal fibrosing alopecia, lichen planopilaris, and FAPD: postmenopausal frontal fibrosing alopecia has been described in association with lichen planus elsewhere (oral cavity)¹⁷ and without evidence of coexistent AGA.^{15,16} We observed postmenopausal frontal fibrosing alopecia-type changes in 3 patients with FAPD.

Finally, the recently proposed concept of central centrifugal scarring alopecia (L. C. Sperling, oral communication, March 1999) might well include FAPD, in addition to pseudopelade and follicular degeneration syndrome, but it does not discriminate between these clinicopathologic entities, which share the late features of the scarring process but clearly differ in their early histological manifestations and clinical features.¹⁸ Regardless of debates about whether pseudopelade of Brocq represents a variant of lichen planopilaris,^{11,12} and whether the follicular degeneration syndrome represents the late stage of dissecting cellulitis of the scalp¹⁹ or any other inflammatory fibrosing alopecia in the black patient, these can clearly be differentiated from FAPD on the basis of clinical features (regular pattern of the fibrosing process in FAPD vs multifocal scarring alopecia in pseudopelade of Brocq) and histological features (lichenoid inflammation targeting the upper follicle region in FAPD vs premature degeneration of the inner root sheath and migration of the hair shaft through the outer root sheath in follicular degeneration syndrome).

Recently, clusters of perifollicular macrophages in healthy murine skin have been described as perhaps indicating the existence of a physiological program of immunologically controlled hair follicle degeneration by which malfunctioning follicles are removed by programmed organ deletion.²⁰ Various forms of clinically perceptible, permanent alopecia might represent pathologi-

cal exaggeration of this type of programmed organ deletion, resulting in a lichenoid tissue reaction pattern and true scarring alopecia. Further studies are required in patients with FAPD to elucidate a presumable role of androgenetic factors in addition to that of the lymphohistiocytic infiltrate, perifollicular lamellar fibrosis, and apoptosis-mediated follicular regression. An important question to be addressed in further studies is how the lichenoid tissue reaction pattern is generated around the individual androgenetic hair follicle. Follicles with some form of damage or malfunction might express cytokine profiles that attract inflammatory cells to assist in damage repair or in the initiation of apoptosis-mediated organ deletion. Alternatively, an as yet unknown antigenic stimulus from the damaged or malfunctioning hair follicle might initiate a lichenoid tissue reaction in the immunogenetically susceptible individual.²¹ The possible role of microbial antigens or superantigens in this context remains to be elucidated.

Inasmuch as FAPD seems to be pathogenetically related to AGA, we prefer regarding it as an entity distinct from other forms of central centrifugal scarring alopecia, especially with respect to therapeutic options. Our preliminary observations of the 4 patients responding to antiandrogenic or finasteride treatment, with decrease of active hair loss and scalp inflammation, supports this notion and underlines the rational basis for such treatment for FAPD. However, FAPD is often diagnosed with delay and well established before introduction of treatment, and destruction of hair follicles in the scarred area is irreversible.

It has been suggested²⁰ that dissecting the molecular controls of immune-mediated, physiological hair follicle degeneration by apoptosis-mediated organ deletion could provide insights into how progression of some forms of permanent alopecia might be halted, which can be suppressed with only limited success by current treatment modalities. We believe that this could also hold true for further studies of FAPD.

Accepted for publication June 21, 1999.

We thank the many Swiss dermatologists who referred individual patients included in this study to the Hair Clinic of the Department of Dermatology, University Hospital of Zurich, Zurich, Switzerland.

Reprints: Ralph M. Trüeb, MD, Department of Dermatology, University Hospital of Zurich, Gloriastrasse 31, CH-8091 Zurich, Switzerland (e-mail: ramitru@derm.unizh.ch).

REFERENCES

1. Lattanand A, Johnson WC. Male pattern alopecia: a histopathologic and histochemical study. *J Cutan Pathol.* 1975;2:58-70.
2. Whiting DA. Diagnostic and predictive value of horizontal sections of scalp biopsy specimens in male pattern androgenetic alopecia. *J Am Acad Dermatol.* 1993; 28:755-763.
3. Sperling LC, Winton GB. The transverse anatomy of androgenetic alopecia. *J Dermatol Surg Oncol.* 1990;16:1127-1133.
4. Jaworsky C, Kligman AM, Murphy GF. Characterization of inflammatory infiltrates in male pattern alopecia: implication for pathogenesis. *Br J Dermatol.* 1992; 127:239-246.
5. Orfanos CE. Androgenetic alopecia: clinical aspects and treatment. In: Orfanos

- CE, Happle R, eds. *Hair and Hair Diseases*. New York, NY: Springer-Verlag NY Inc; 1990:485-527.
6. Kaufmann KD. Androgen metabolism as it affects hair growth in androgenetic alopecia. *Dermatol Clin*. 1996;4:697-711.
 7. Waldorf DS. Lichen planopilaris and alopecia. *Arch Dermatol*. 1966;93:684-691.
 8. Elston DM, Bersfeld WF. Cicatricial alopecia (and other causes of permanent alopecia). In: Olson EA, ed. *Disorders of Hair Growth: Diagnosis and Treatment*. New York, NY: McGraw-Hill, Inc; 1994:285-313.
 9. Mehregan DA, Van Ale HM, Muller SA. Lichen planopilaris: clinical and pathologic study of forty-five patients. *J Am Acad Dermatol*. 1992;27:935-942.
 10. Braun-Falco O, Imai S, Schmoeckel C, et al. Pseudopelade of Brocq. *Dermatologica*. 1986;172:18-23.
 11. Silvers DN, Katz BE, Young AW. Pseudopelade Brocq is lichen planopilaris: report of four cases that support this nosology. *Cutis*. 1993;51:99-105.
 12. Braun-Falco O, Bergner T, Heilgemeir GP. Pseudopelade Brocq-Krankheitsbild oder Krankheitsentität? *Hautarzt*. 1989;40:77-83.
 13. Sperling LC, Sau P. The follicular degeneration syndrome in black patients. *Arch Dermatol*. 1992;128:68-74.
 14. Sperling LC, Skelton HG, Smith KJ, Sau P, Friedman K. Follicular degeneration syndrome in men. *Arch Dermatol*. 1994;130:763-769.
 15. Kossard S. Postmenopausal frontal fibrosing alopecia: scarring alopecia in a pattern distribution. *Arch Dermatol*. 1994;130:770-774.
 16. Kossard S, Lee MS, Wilkinson B. Postmenopausal frontal fibrosing alopecia: a frontal variant of lichen planopilaris. *J Am Acad Dermatol*. 1997;36:59-66.
 17. Trüeb RM, Toricelli R. Lichen planopilaris unter dem bild einer postmenopausalen frontalen fibrosierenden Alopezie (Kossard). *Hautarzt*. 1998;49:388-391.
 18. Templeton SF, Solomon AR. Scarring alopecia: a classification based on microscopic criteria. *J Cutan Pathol*. 1994;21:97-109.
 19. Gibbons G, Ackerman AB. Resolving quandaries: follicular degeneration syndrome? *Dermatol Dermatopathol Pathol Pract Concept*. 1995;1:197-200.
 20. Eichmuller S, van der Veen C, Moll L, et al. Clusters of perifollicular macrophages in normal murine skin: physiological degeneration of selected hair follicles by programmed organ deletion. *J Histochem Cytochem*. 1998;46:361-370.
 21. Boyd AS, Neldner KH. Lichen planus. *J Am Acad Dermatol*. 1991;25:593-619.

Submissions for Special Features

Critical Situations

Readers are invited to submit examples of newly described disorders, the use of new diagnostic technology, dermatologic manifestations of important social disorders such as child abuse, and cases that highlight the complex nature of acute care dermatology to Anita G. Licata, MD, Division of Dermatology, UHC, 1 S Prospect St, Burlington, VT 05401-3444. When appropriate, these should be written in case presentation format with a brief discussion following.

The Cutting Edge

Clinicians, local and regional societies, residents, and fellows are invited to submit cases of challenges in management and therapeutics to this section. Cases should follow the established pattern and be submitted double-spaced and in triplicate. Photomicrographs and illustrations must be clear and submitted as positive color transparencies (35-mm slides) or black-and-white prints. Do not submit color prints unless accompanied by original transparencies. Material should be accompanied by the required copyright transfer statement, as noted in "Instructions for Authors." Material for this section should be submitted to George J. Hruza, MD, Director, Laser & Dermatologic Surgery Center, Inc, 14377 Woodlake Dr, Suite 111, St Louis, MO 63017. Reprints are not available.

Issues in Dermatology

Issues in Dermatology solicits provocative essays relevant to all aspects of dermatology. Please submit manuscripts to the section editor, Kenneth A. Arndt, MD, Beth Israel Deaconess Medical Center, 330 Brookline Ave, LY 127-1, Boston, MA 02215.

Off-Center Fold

Clinicians, local and regional societies, and residents and fellows in dermatology are invited to submit quiz cases to this section. Cases should follow the established pattern and be submitted double-spaced. Photomicrographs and illustrations must be clear and submitted as positive color transparencies. Material should be accompanied by the required copyright transfer statement, as noted in "Instructions for Authors." Material for this section should be submitted to Michael E. Ming, MD, Dermatopathology Section, University of California, San Francisco, 1701 Divisadero St, Suite 334, San Francisco, CA 94115. Reprints are not available.